

## Introduction

This work is intended as an introductory synopsis for medical students and junior residents. Copies may be downloaded in Adobe PDF format at no cost from the Web address provided below. Suggestions for improvement are always appreciated and can be sent to me at [djdoyle@hotmail.com](mailto:djdoyle@hotmail.com).

<http://airwaymicrotext.homestead.com>

## Acknowledgements / Peer Review

I am especially grateful to Vladimir Nekhendzy, M.D., Clinical Associate Professor of Anesthesia and Otolaryngology, Stanford University School of Medicine, who carefully reviewed the previous edition and made many helpful suggestions that were incorporated into the current edition.

### ABBREVIATIONS USED

ASA	American Society of Anesthesiologists
CO <sub>2</sub>	carbon dioxide
ETCO <sub>2</sub>	end-tidal CO <sub>2</sub>
ETT	endotracheal tube
FI <sub>O2</sub>	fraction of inspired oxygen
FGF	fresh gas flow
FOB	fiberoptic bronchoscope
GA	general anesthesia
IV	intravenous
LMA	laryngeal mask airway
N <sub>2</sub> O	nitrous oxide
O <sub>2</sub>	oxygen
OSA	obstructive sleep apnea
PaCO <sub>2</sub>	partial pressure of CO <sub>2</sub>
PaO <sub>2</sub>	partial pressure of O <sub>2</sub>
PPV	positive pressure ventilation
PSI	pounds per square inch
RR	respiratory rate
RSI	rapid sequence induction / intubation
TMJ	temporomandibular joint
TTJV	transtracheal jet ventilation
TV	tidal volume

## Goals of Clinical Airway Management

### 1. Oxygenation

Oxygenation is controlled via the fraction of inspired oxygen (FI<sub>O2</sub>), although PEEP adjustment is equally important to improve oxygenation in ventilated patients with acute lung injury (PEEP or positive end expiratory pressure, is the minimum lung distending pressure over expiration; it is usually set between 2 and 5 cm H<sub>2</sub>O in patients with normal lungs). The minimum FI<sub>O2</sub> used in anesthesia is usually 0.3 (30%) and can be increased to 1.0 (100%) by decreasing the concentration of N<sub>2</sub>O or air administered. Adjust FI<sub>O2</sub> / PEEP to keep arterial saturation above 95% (using a pulse oximeter) or PaO<sub>2</sub> between 100 and 150 mm Hg in patients where arterial lines are available for arterial blood gas analysis.

### 2. Ventilation

In spontaneous ventilation, negative pressure inside the lungs from diaphragmatic flattening draws in air. With positive pressure ventilation (PPV) gas is forced into the lungs using a positive pressure source such as a manual resuscitator or a automatic ventilator. PPV is often facilitated with muscle relaxation but it is not always necessary. Ventilation is determined by adjusting two parameters: tidal volume (TV) and respiratory rate (RR). Start with TV=10 ml/kg and RR=10/min and then adjust according to ETCO<sub>2</sub> or PaCO<sub>2</sub>. On some machines the tidal volume delivered depends on the total fresh gas flow (FGF), often set between 1 and 6 liters/min (flows of 1-2 liters/min are most economical).

### 3. Protection of the Airway from Injury

A final important goal of clinical airway management is preventing lung injury that may result from various causes such as [1] gastric contents spilling into the lungs (aspiration pneumonia), [2] retention of secretions that may lead to pneumonia, or [3] partial lung collapse (atelectasis). The prevention of aspiration in unconscious patients (generally those under general anesthesia or patients with a head injury) is usually achieved by using a cuffed endotracheal tube; unintubated patients may develop deadly aspiration pneumonia if stomach contents spill into the lungs (especially if the pH is < 2.5 or volume > 25 ml). Patients at risk of aspiration with the induction of general anesthesia are usually managed with either a rapid sequence induction (RSI) or with awake intubation. (See also Tables 6 and 7 and Figure 2)

### TABLE 1 - Major Airway Management Options for Clinical Anesthesia Delivery

- Avoid general anesthesia - use local/regional anesthesia.
- General anesthesia (GA) with spontaneous breathing and an unprotected airway (e.g. using face mask, nasal cannula, oral airway, nasopharyngeal airway, or nothing).
- General anesthesia using a Laryngeal Mask Airway (LMA), Combitube, or other supraglottic airway device with patient spontaneously breathing (airway somewhat protected against aspiration with correct positioning [especially with the LMA ProSeal], but less so as compared to using a cuffed ETT).
- General anesthesia with spontaneous breathing and an airway protected using a cuffed endotracheal tube. An uncuffed tube is still popular with children, but provides less complete protection of the airway against aspiration.
- General anesthesia with positive pressure ventilation (PPV) and an endotracheal tube (ETT). **MOST COMMON SITUATION FOR BIG SURGICAL PROCEDURES.**
- General anesthesia with PPV but using the laryngeal mask airway (LMA) (esp. LMA ProSeal), Combitube, or other supraglottic airway device.
- Surgical airway (e.g. tracheostomy under local anesthesia, emergency cricothyroidotomy).
- Transtracheal jet ventilation (*special circumstances*)
- Apneic oxygenation (*special circumstances*)

**TABLE 2 - Some Factors in Airway Evaluation**

**History** Patient provides a "difficult intubation" letter. Previous difficulty with intubation (review old records or reports that a previous intubation was done awake. Patient reports of dental trauma at a previous intubation. Be especially careful of a patient with a tracheostomy scar, since the trachea may now be narrowed (subglottic stenosis).

**Mouth opening** Should be adequate (3 cm or more) to easily allow a laryngoscope to enter into the oropharynx. Patients with temporomandibular joint (TMJ) disease or trismus may not be able to open widely, and may require fiberoptic intubation by the nasal route. [See figure on right side]

**Mallampati class** Rated from I to IV (see Figure 1B)

**Thyromental distance** Distance from the mentum of the mandible to the thyroid, with neck fully extended. If distance is less than 6 cm there is less space for the tongue to be displaced with laryngoscopy.

**Teeth** Edentulous patients are always easier to intubate, but are often more difficult to ventilate with a face mask. Patients with teeth in poor condition or with very prominent teeth may be more difficult to intubate.

**Tongue** Patients with a large, immobile or edematous tongue may be more difficult to intubate.

**Neck thickness** Patients with a thick neck tend to be more difficult to intubate.

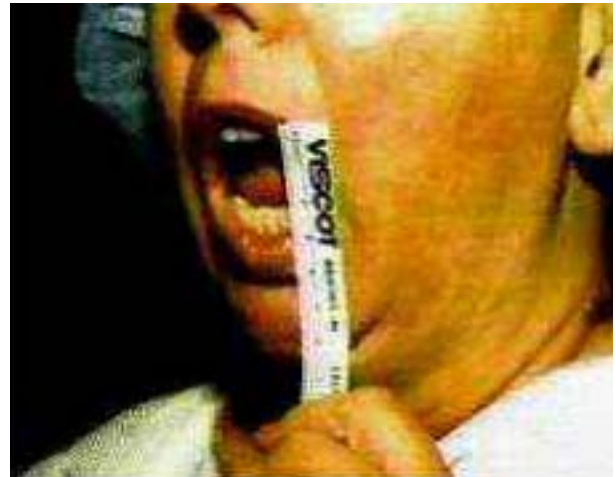**Head mobility** Limited neck extension is associated with poor laryngeal view and difficult intubation. Almost all of the extension of the neck takes place at the atlantooccipital joint. Patients with immobile heads (e.g. ankylosing spondylitis) may not be able to be positioned into the "sniffing position" (In the sniffing position, the neck is flexed with the head extended. Conventional wisdom (*now disputed, see Anesthesiology 95:825-7*) holds that this is the best position for intubation.)

Sufficient **submandibular tissue compliance** is required for the forward displacement of oral structures at intubation. Patients with stiff, indurated or nonresilient submandibular tissues, or tissues occupied by a mass (tumor, abscess) can be difficult to intubate.

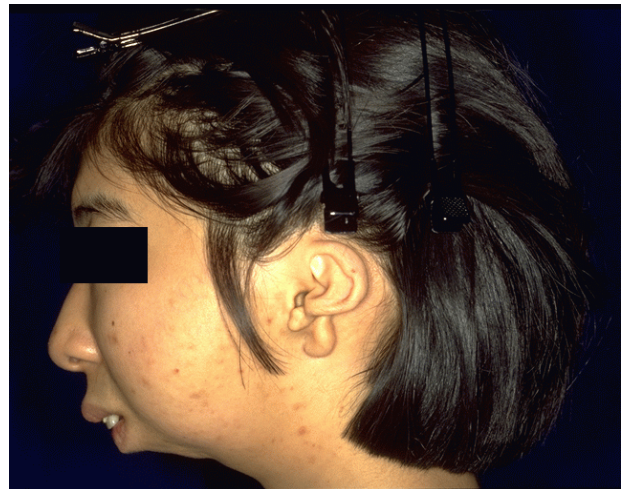**Mandibular protrusion** Patients should be able to bring their mandibular incisors anterior to their maxillary incisors.

**OTHER** By combining the Mallampati score and thyromental distance, Frerk showed that patients who were Mallampati Grade 3 or 4 and who also had a thyromental distance of less than 7cm were likely to be difficult to intubate. See *Frerk CM. Predicting difficult intubation. Anaesthesia 1991;46:1005-8*

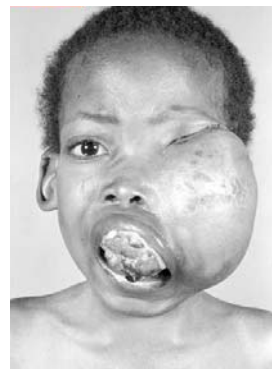**IMPORTANT NOTE** – In the May 2003 issue of the journal *Anesthesiology* the ASA Difficult Airway Taskforce identified a series of findings on physical examination that suggest that intubation may be more difficult than usual. See the following article for details: Practice Guidelines for Management of the Difficult Airway: An Updated Report by the American Society of Anesthesiologists Task Force on Management of the Difficult Airway. *Anesthesiology*: Vol. 98 May 2003 pp 1269-1277



Limited mouth opening as a result of TMJ disease. Source: <http://www.achi.com/jpg/fig70.jpg>



This young lady with **micrognathia** would be difficult to intubate by ordinary means since there is very little room for the tongue to be displaced when using of an ordinary laryngoscope. **Pierre Robin syndrome** (also called Pierre Robin complex or sequence) is one of several congenital conditions associated with micrognathia. Other causes of micrognathia include **Treacher-Collins syndrome**, **Russell-Silver syndrome** and **Cri du chat syndrome**. Such patients are often intubated using a flexible fiberoptic bronchoscope. (Image credit - <http://www.med.osakau.ac.jp/pub/anes/www/airway/img0001.gif>)



This unfortunate pediatric patient would be difficult to intubate by ordinary means because of a large tumor in his left cheek. In the days before fiberoptic intubation (and even now in some countries) such patients would be managed by tracheostomy under local anesthesia or by awake retrograde intubation. Source: <http://www.nda.ox.ac.uk/wfsa>

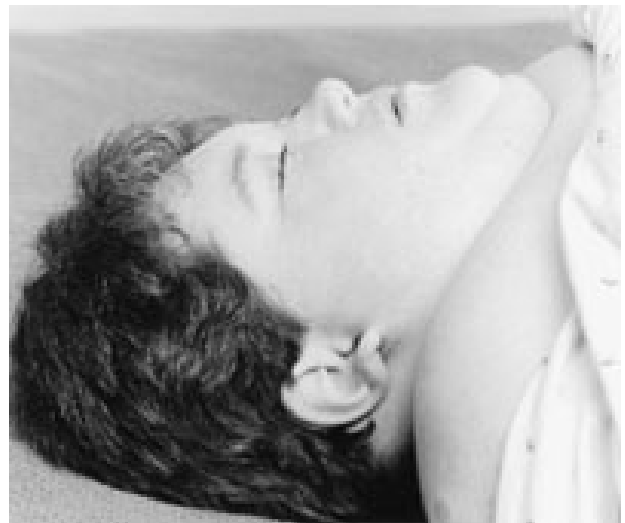Selected congenital syndromes associated with difficult endotracheal intubation (from Miller 6 <sup>th</sup> Ed)	
Syndrome	Description
Down	Large tongue, small mouth make laryngoscopy difficult; small subglottic diameter possible
	Laryngospasm is common.
Goldenhar (oculoauriculo-vertebral anomalies)	Mandibular hypoplasia and cervical spine abnormality make laryngoscopy difficult.
Klippel-Feil	Neck rigidity because of cervical vertebral fusion
Pierre Robin	Small mouth, large tongue, mandibular anomaly; awake intubation essential in neonate
Treacher Collins (mandibulofacial dysostosis)	Laryngoscopy is difficult.
Turner	High likelihood of difficult intubation

TABLE 3 - Predictors of Difficult Mask Ventilation

- Age over 55 years
- Body mass index exceeding 26 kg/m<sup>2</sup>
- Presence of a beard
- Lack of teeth (edentulous)
- History of snoring

Source: Anesthesiology 2000; 92: 1229

AVAILABLE FREE ONLINE AT [www.anesthesiology.org](http://www.anesthesiology.org)

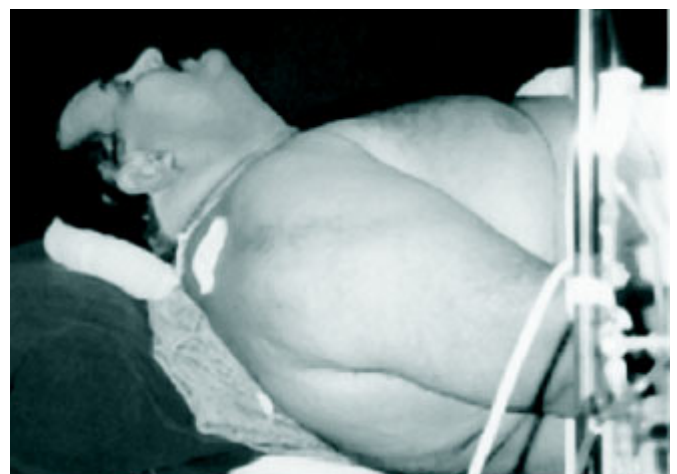

Obese individuals such as shown above may be both difficult to ventilate but also difficult to intubate as a result of redundant folds of oropharyngeal tissue and decreased chest wall compliance. The use of a jaw thrust maneuver (see figure to the left) and airway adjuncts such as a nasopharyngeal airway can be very useful in many cases. When intubating such patients, special attention should be placed to positioning the patient with his or her head and shoulders placed on a series of towels or folded blankets (or using special intubation pillow) to facilitate laryngoscopy and intubation (see image below).

Image credits:

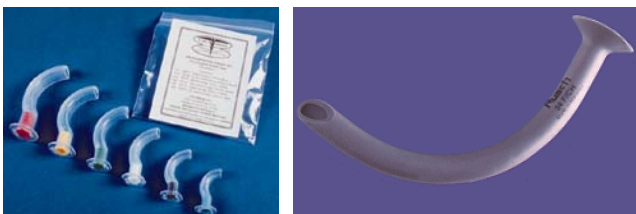Above: <http://www.rjmatthewsmd.com/Definitions/img/osa-6b.png>

Below: [http://www.scielo.br/img/revistas/rba/v55n2/en\\_a12f2i.jpg](http://www.scielo.br/img/revistas/rba/v55n2/en_a12f2i.jpg)



### Bag and Mask Ventilation

Bag and mask ventilation is an important clinical skill to master. In most resuscitation settings a self-reinflating bag with nonbreathing valves (such as that shown below) is used to provide positive pressure ventilation, usually using 100% oxygen. This bag fills spontaneously after being squeezed and can be used even when oxygen is unavailable. Ventilation is often made much easier when the "jaw thrust maneuver" is carried out. Oropharyngeal or nasopharyngeal airways can also be helpful. Following prolonged bag and mask ventilation, a nasogastric tube may be used to vent any air that has been forced into the stomach.



Oropharyngeal Airways      Nasopharyngeal Airway

**Difficult mask ventilation** is said to occur when "it is not possible for the unassisted anesthesiologist to maintain the oxygen saturation above 90 percent using 100 percent oxygen and positive pressure mask ventilation in a patient whose oxygen saturation was above 90 percent before anesthetic intervention" or when "it is not possible for the unassisted anesthesiologist to prevent or reverse signs of inadequate ventilation during positive pressure mask ventilation" (ASA definitions).

### Pulse Oximetry

Pulse oximetry is a simple non-invasive method of monitoring arterial oxygen saturation, the percentage of hemoglobin (Hb) with oxygen molecules attached. The pulse oximeter consists of a probe attached to the patient's finger, toe or ear lobe which is in turn attached to the main unit. In some units an audible tone occurs with each heart beat and changes pitch with the saturation reading. A pulse oximeter detects hypoxia before well the patient becomes clinically cyanosed and is required in ALL patients undergoing anesthesia. Note that pulse oximeters give no information about the level of arterial CO2 and are therefore useless in assessing the CO2 in patients at risk of developing hypercarbic respiratory failure. Units are now available for well under \$1000.



**TABLE 4 – Criteria for Oxygen Therapy**

*Suggestions from a National Consensus Conference*

- Cardiac or respiratory arrest
- Hypoxemia of any cause
  - Arterial O2 tension < 60 mm Hg
  - Arterial O2 saturation < 90%
- Hypotension
  - Systolic blood pressure <90 mm Hg
- Metabolic acidosis
  - Bicarbonate concentration < 18 mEq/L
- Respiratory distress
  - Respiratory rate > 24 breaths/min
  - Use of accessory muscles of respiration
- Prevention of postoperative hypoxemia

**TABLE 5 - Management of Hypoxemia**

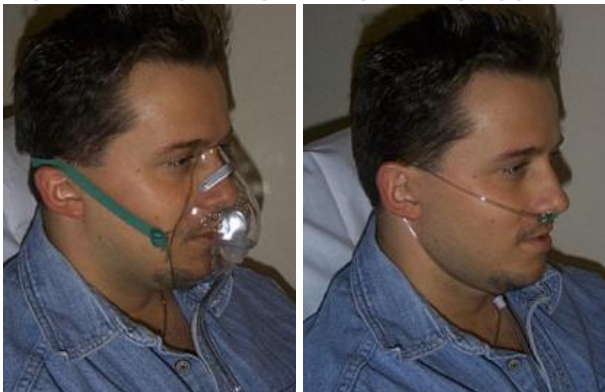- Apply supplementary oxygen by face mask.
- Use 100% oxygen delivered by bag and mask or by non-rebreather face mask if patient is very hypoxemic or very sick.
- Intubate and ventilate patient if clinically indicated.
- Investigate the cause of hypoxemia and treat cause where possible (e.g. hypercarbia).
- Titrate oxygen to achieve a particular target arterial oxygen saturation (e.g. 94-97%) using a pulse oximeter.
- In intubated patients: Apply increases in Positive End Expiratory Pressure (PEEP) in conjunction with increases in inspired oxygen tension to counter hypoxemia due to shunting (e.g., ARDS, pneumonia).
- Avoid oxygen toxicity by avoiding hyperoxia.

*Hypoxemia exists if the arterial oxygen tension is under 60 mm Hg (measured by ABGs) or the arterial saturation is under 90% (measured by pulse oximeter). Continuous pulse oximetry monitoring can be very valuable in patients at special risk, such as postoperative patients with obstructive sleep apnea (OSA).*

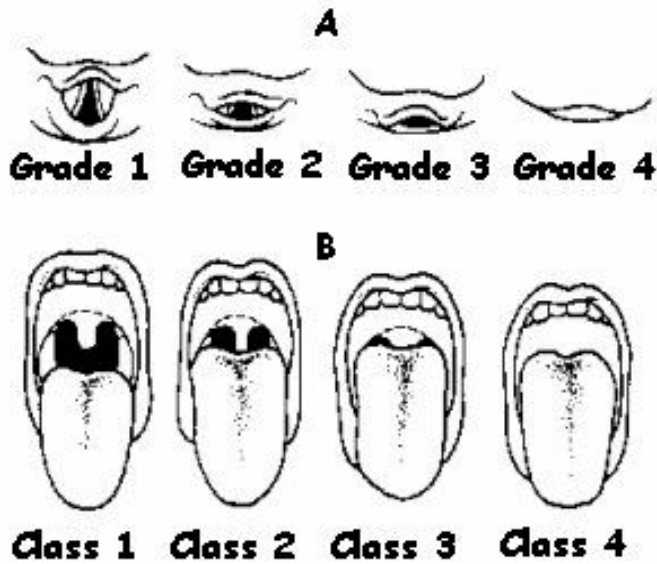
### Oxygen Delivery

Oxygen may be given by one of five routes: face mask (of which there are a variety of types), nasal prongs, endotracheal tube, oxygen tent, and transtracheal catheter. The last two methods are used only occasionally. For more information visit <http://www.lhsc.on.ca/respthrapy/rtequip/oxygen/index.htm> (source of images below)

**SIMPLE FACE MASK    NASAL PRONGS**



**HISTORICAL DIVERSION** Iron lungs are negative pressure ventilators. They were first tested on humans in 1928 by Philip Drinker at Harvard university. Soon there were thousands of units in use - most in patients paralyzed by polio. (The first polio vaccine was in 1954.) Iron lung technology utilizes "negative pressure" ventilation, cyclically sucking air out of a body chamber. Iron lungs are still used - see story at [news.bbc.co.uk/1/hi/health/3182096.stm](http://news.bbc.co.uk/1/hi/health/3182096.stm)  
Photo: [www.fda.gov/cber/summaries/cent092302pp\\_25.gif](http://www.fda.gov/cber/summaries/cent092302pp_25.gif)



**FIGURE 1 – Two Important Airway Classifications**

[Source: [www.pdh-odp.co.uk/intubation\\_grades.htm](http://www.pdh-odp.co.uk/intubation_grades.htm)]

**A** Cormack and Lehane classification of the view at laryngoscopy. (Cormack RS, Lehane J: *Difficult tracheal intubation in obstetrics. Anaesthesia* 39: 1105, 1984)

- Grade I:** most of the glottis is seen
- Grade II:** only posterior portion of glottis can be seen
- Grade III:** only epiglottis seen (none of glottis seen)
- Grade IV:** neither epiglottis nor glottis can be seen

**B** Mallampati classification of the oropharyngeal view. (Mallampati SR, Gatti SP, Gugino LD: *A clinical sign to predict difficult intubation: a prospective study. Can Anaesth Soc J* 32: 429-434, 1985) Do with patient sitting, the head in the neutral position, the mouth wide open, and the tongue protruding to the maximum. The patient should not be phonating. The Mallampati classification is then assigned based upon the visible pharyngeal structures.

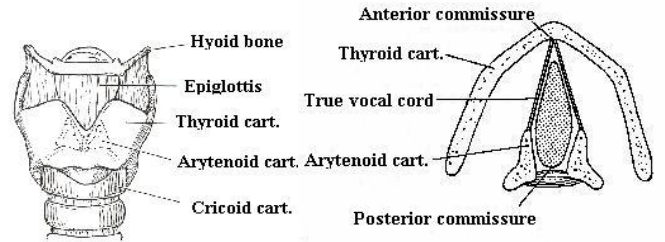
- Class I:** visualization of the soft palate, fauces, uvula, anterior and posterior pillars.
- Class II:** visualization of the soft palate, fauces and uvula.
- Class III:** visualization of the soft palate and base of uvula.
- Class IV:** soft palate is not visible.

### Laryngeal Anatomy

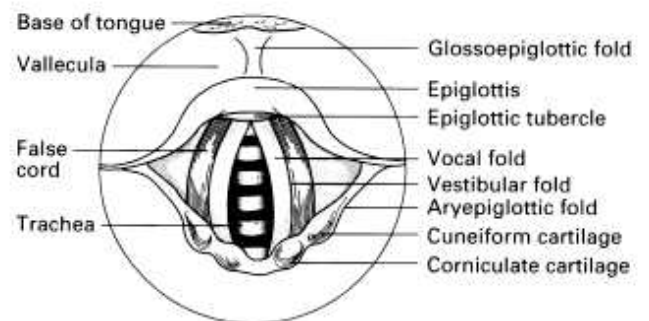
The larynx lies anterior to C4, C5, and C6 and is composed of nine articulating cartilages, three of which are paired (arytenoid, corniculate and cuneiform cartilages) and three of which are unpaired (thyroid, cricoid and epiglottic cartilages). The epiglottic cartilage overhangs the laryngeal inlet like a door. Thyrohyoid, cricothyroid and cricotracheal ligaments or membranes stabilize and connect the cricoid and thyroid cartilages. The vocal ligaments attach to the angles of the thyroid cartilage anteriorly and to the arytenoids cartilage posteriorly; they form the framework of the vocal cords. The triangular fissure between the vocal cords is known as the glottic opening. The nine intrinsic muscles (four paired and one unpaired) of the larynx are classified as: (1) abductors of the cords; (2) adductors of the cords; (3) regulators of the vocal cord tension. The posterior cricoarytenoid muscles are the only cord abductors; they create the glottic opening by rotating the arytenoid cartilages so that the vocal processes move laterally. The lateral cricoarytenoid muscles adduct the

cords and close the glottis by rotating the arytenoid cartilages in the reverse direction. The cricothyroid muscle tenses the vocal cords. Source: *Miller's Anesthesia, Second Edition*

Anatomical view of the larynx from the front [left panel, below] and the top [right panel, below]



View of the larynx at laryngoscopy (below)



<http://www.4um.com/tutorial/anaesth/rsi.htm>

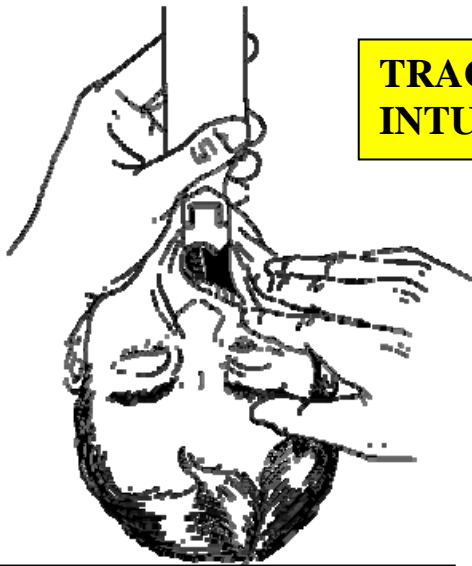
The **motor supply for the larynx** = recurrent laryngeal nerves (branch of the vagus n.) except for the cricothyroid.

### Sensory Innervation of the Pharynx and Larynx

- **Pharynx:** via the GLOSSOPHARYNGEAL NERVE.
- **Larynx:** via branches of the VAGUS NERVE.

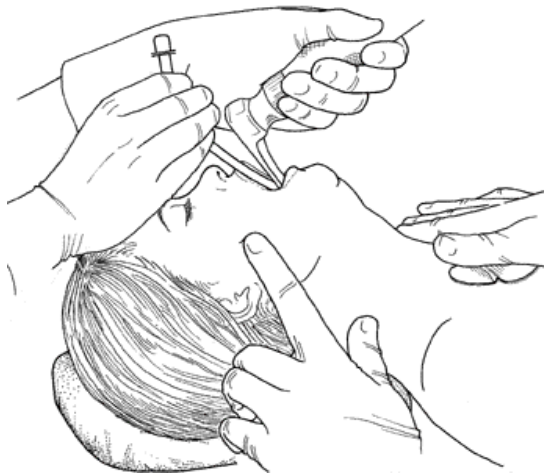(Above the vocal folds the sensory innervation of the larynx is via the INTERNAL LARYNGEAL NERVE. Below the vocal folds it is by way of branches of the RECURRENT LARYNGEAL NERVE.)

Laryngeal Innervation (from Miller's Anesthesia 6 <sup>th</sup> Ed)		
Nerve	Sensory	Motor
Superior laryngeal (internal division)	Epiglottis, base of tongue	None
	Supraglottic mucosa	
	Thyroepiglottic joint	
Superior laryngeal (external division)	Anterior subglottic mucosa	Cricothyroid (adductor, tensor)
	Recurrent laryngeal	Subglottic mucosa
	Muscle spindles	Lateral cricoarytenoid
		Interarytenoid (adductors)
		Posterior cricoarytenoid (abductor)

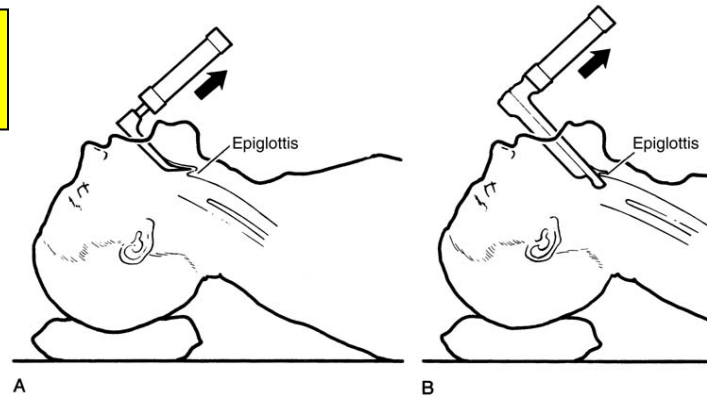


**TRACHEAL INTUBATION**

**Top** – view of intubation from the perspective of the intubator.  
**Bottom** – side view of intubation.  
 Notice that the laryngoscope is held with the left hand, while the endotracheal tube is passed using the right hand.



**Endotracheal Tube (ETT) with cuff at distal end.**



Proper position of the laryngoscope blade during direct laryngoscopy for exposure of the glottic opening.

**A**, The distal end of the curved blade is advanced into the space between the base of the tongue and pharyngeal surface of the epiglottis (i.e., vallecula).

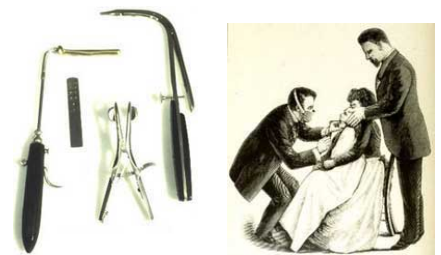
**B**, The distal end of the straight blade (Jackson-Wisconsin or Miller) is advanced beneath the laryngeal surface of the epiglottis. Regardless of blade design, forward and upward movement exerted along the axis of the laryngoscope blade (arrows) elevates the epiglottis and exposes the glottic opening.

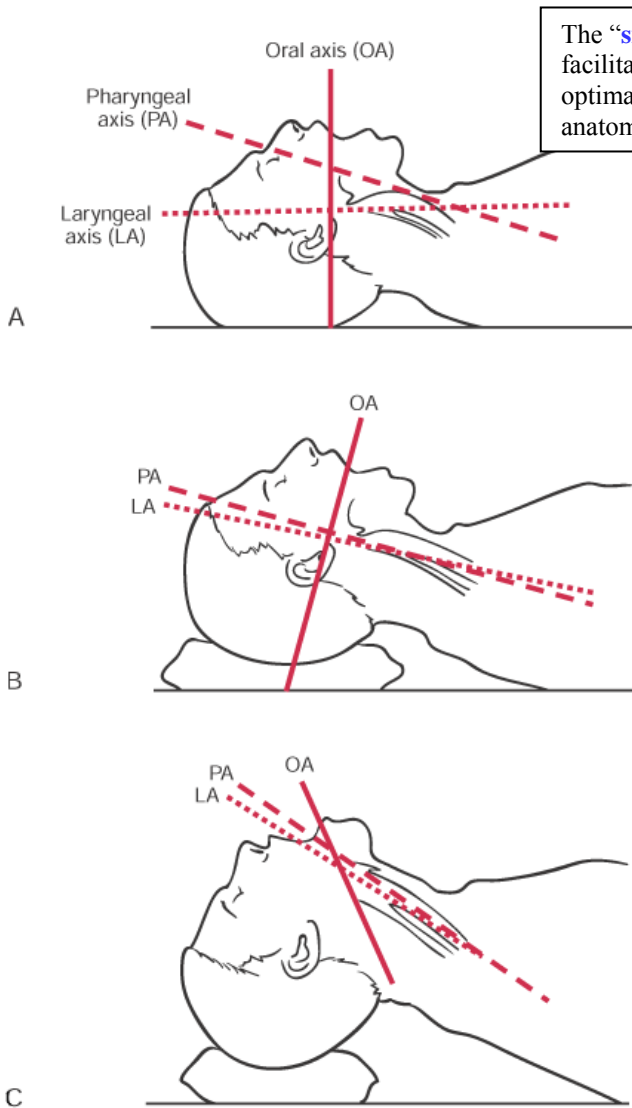
(Image and figure legend from Miller 6<sup>th</sup> Ed)

**TABLE 5 - Possible Indications for Intubation**  
 [Modified from <http://www.fpnotebook.com/LUN127.htm>]

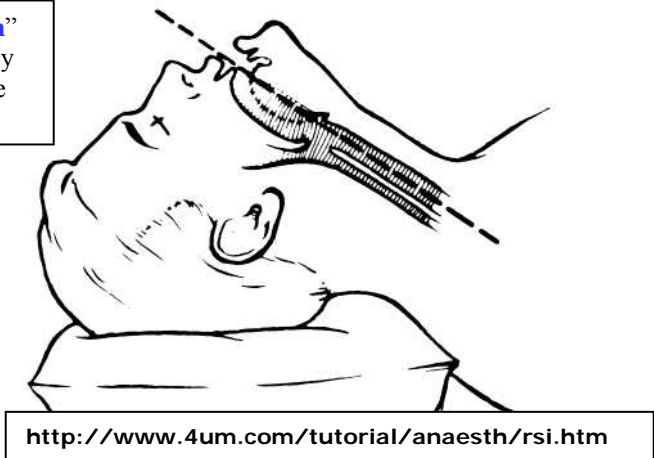
- Delivery of general anesthesia
- Respiratory or cardiac arrest
- Respiratory failure
  - Hypoventilation/hypercarbia (PaCO<sub>2</sub> >55 mmHg )
  - Refractory hypoxemia
  - Respiratory acidosis
- Airway obstruction
- Glasgow Coma Scale <=8
- Need for prolonged ventilatory support
- Class III or IV hemorrhage with poor perfusion
- Severe flail chest or pulmonary contusion
- Trauma, head injury or abnormal mental status
- Inhalation injury with erythema / edema at cords
- Need for protection from aspiration

**HISTORICAL DIVERSION** Diphtheria (*corynebacterium diphtheriae*), an acute bacterial infection spread by personal contact, was the most feared of all childhood diseases. One child out of every ten that became infected died from this disease. Symptoms ranged from a severe sore throat to suffocation by the formation of a 'false membrane' over the larynx. Between 1880 and 1887, Joseph O'Dwyer devised a series of tubes to be inserted into the larynx and thus maintain air supply until the crisis period of the illness passed. O'Dwyer's intubation tubes were not foolproof, nor simple to use, but desperate doctors and parents grasped this innovation as a precious last resort. The American medical community hailed O'Dwyer, a Cleveland native, as the medical savior of thousands of children in the United States. From <http://www.cwru.edu/artsci/dittrick/site2/museum/artifacts/group-b/b-3intubation.htm> The images on the right show the instruments used by O'Dwyer to insert his tube to establish a patent airway, as well as a drawing of a child (being held by his mother) being intubated. Occasionally the child would bite the intubator, resulting in some physicians tragically dying from diphtheria as a result.

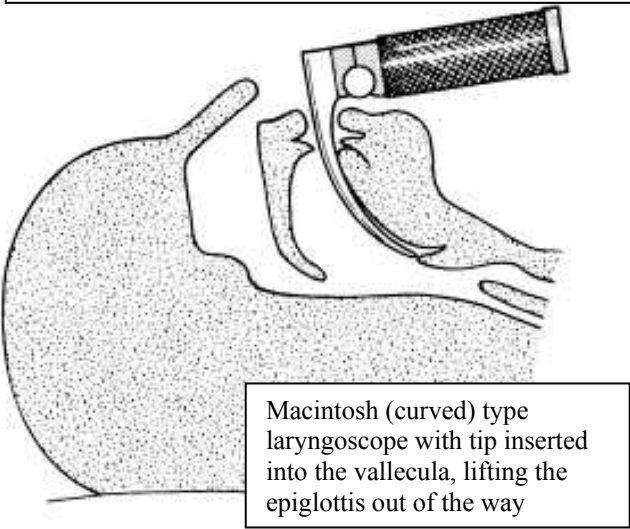




The "sniffing position" facilitates intubation by optimally lining up the anatomical structures.



<http://www.4um.com/tutorial/anaesth/rsi.htm>



Macintosh (curved) type laryngoscope with tip inserted into the vallecula, lifting the epiglottis out of the way



Collection of laryngoscope blades. On the left, the curved Macintosh type and on the right, the straight Miller type blade.

**Schematic diagram demonstrating the head position for endotracheal intubation.**

**A,** Successful direct laryngoscopy for exposure of the glottic opening requires alignment of the oral, pharyngeal, and laryngeal axes.  
**B,** Elevation of the head about 10 cm with pads below the occiput and with the shoulders remaining on the table aligns the laryngeal and pharyngeal axes.  
**C,** Subsequent head extension at the atlanto-occipital joint creates the shortest distance and most nearly straight line from the incisor teeth to glottic opening. (Image and figure legend from Miller 6<sup>th</sup> Ed)



**HISTORICAL DIVERSION** Tracheostomy tube materials have certainly evolved since 160 AD when Galen wrote, "If you take a dead animal and blow air through its larynx (through a reed), you will fill its bronchi and watch its lungs attain the greatest dimension." In 1869, Trendelenburg first proposed the use of a cuffed tracheostomy tube. On the left is shown an antique sterling silver tracheostomy tube set, made in England in the late 1800's. Outer cannulas are shown on the left and right, with an inner cannula shown in the center. From [www.tracheostomy.com](http://www.tracheostomy.com)

**TABLE 6 - Popular and Specialty Laryngoscopes**

**“Conventional” Laryngoscopes**

- Macintosh type laryngoscopes (curved blades)
- Miller type laryngoscopes and other straight blade designs
- McCoy laryngoscope and variants (articulating tip)

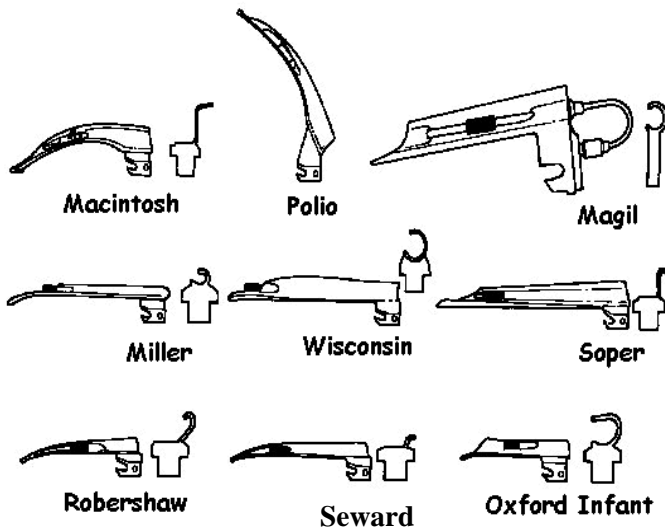
**Rigid Fiberoptic Laryngoscopes**

- Bullard laryngoscope
- Upsher laryngoscope
- Wu laryngoscope (WuScope)

**Video Laryngoscopes (with microminiature TV camera)**

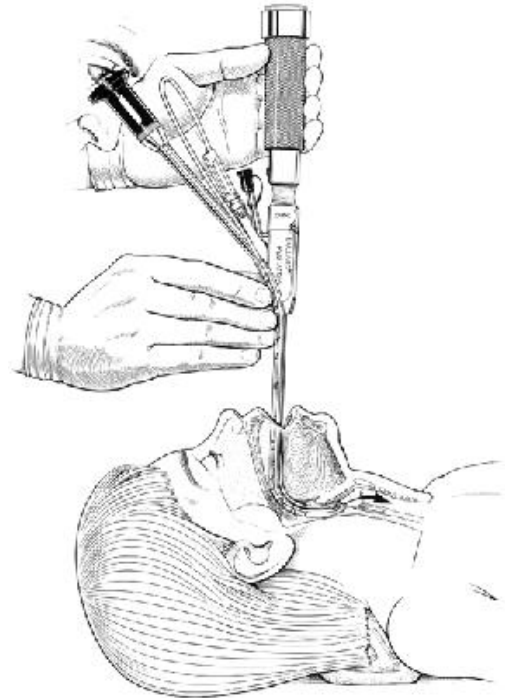
- GlideScope Video Laryngoscope (see glidescope.net)
- Storz Video Laryngoscope (Video Macintosh System)
- Weiss Video Laryngoscope

**Flexible Fiberoptic Laryngoscopes (Bronchoscopes)**



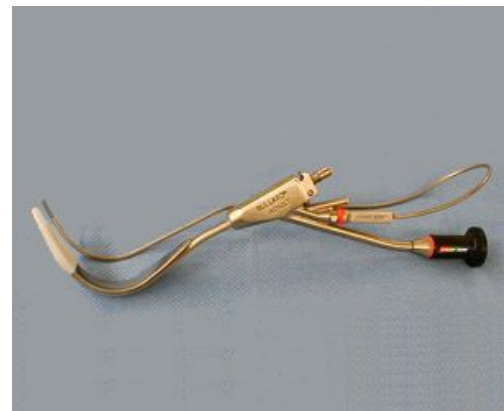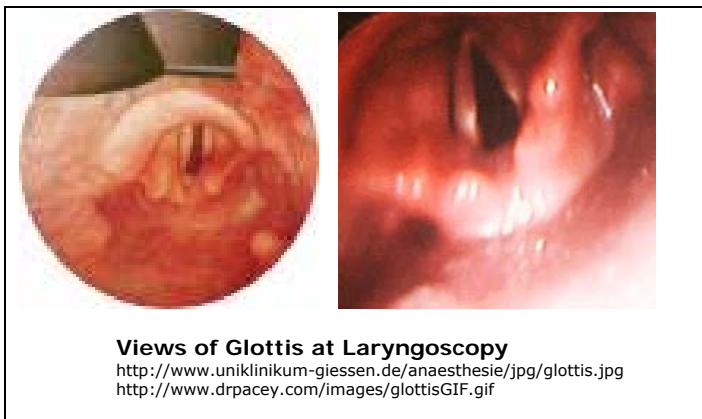**Bullard Laryngoscope**

This rigid fiberoptic laryngoscope allows visualization of the glottis even when there is an inability to align the oral, pharyngeal, and laryngeal axes, perhaps because the patient has limited flexion/extension. In one study the Bullard laryngoscope caused less head extension and cervical spine extension than conventional laryngoscopes and resulted in a better view, suggesting that it may be useful in care of patients in whom cervical spine movement is limited or undesirable (Anesthesiology 1995;82:859). For additional information visit <http://www.anest.ufl.edu/~eduweb/airway/bullard/bullard.html>



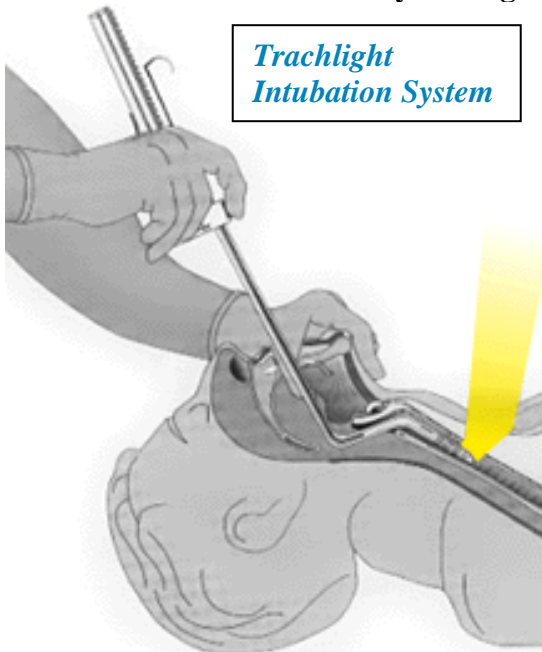
<http://www.anest.ufl.edu/~eduweb/airway/bullard/bullardassembled.jpg>

**SOME TYPES OF LARYNGOSCOPE BLADES**



**HISTORICAL DIVERSION** “It was a frigid afternoon that day in Virginia December 1799 as three physicians gathered around a dying man. The man kept shifting his position, as he gasped for air. The physicians gave the man sage tea with vinegar to gargle but it nearly caused the patient to choke to death. It was obvious the patient’s airway was severely compromised but poultices did little to help. It had only been a year since the medical literature of the time described a surgical procedure in which the trachea could be accessed in cases of airway obstruction. In 1799, even elective tracheotomy, let alone emergent tracheotomy were rarely performed. The patient’s condition continued to deteriorate as he struggled for breath. One of the physicians was aware of the tracheotomy procedure but was reluctant to attempt it on such a famous person because the procedure was considered futile and irresponsible. Soon the patient became calm and relaxed. The patient took his finger and felt for his pulse as he had seen his physicians do many times. His attending physicians never learned the result as his fingers slipped from his wrist and he died. History buffs may recognize this story as the death of George Washington. While arguments still persist about the cause of Washington’s death, the most popular theory is that he died from an upper airway obstruction caused by bacterial epiglottitis.” **From tracheostomy.com**





Based upon the principle of transillumination of the soft tissues of the neck, the Trachlight is a blind intubation method that has a high success rate in well-trained hands.

**Some Uses:**

- Routine endotracheal intubation
- Limited mouth opening
- Reduced neck flexion / extension
- Difficult or failed intubation
- Bloodied airway

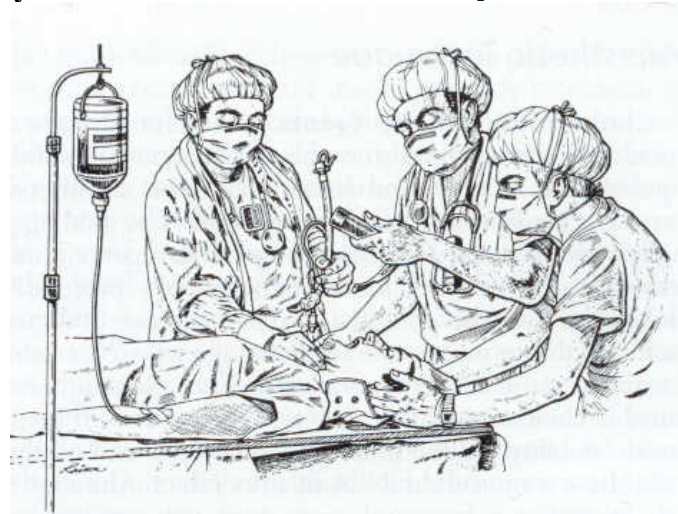**Contraindications:**

- Pharyngeal abscesses or masses
- Anatomic pathology or trauma in the upper airway

For additional information see Can J Anesth 2001 48: 592-599, available free at [www.cja-jca.org](http://www.cja-jca.org)

**TABLE 7 - Factors Leading to Increased Risk of Pulmonary Aspiration with General Anesthesia**

- Recent food or fluid ingestion
- Severe obesity
- Symptoms of gastroesophageal reflux
- Advanced pregnancy
- Severe ascites
- Opioid administration or other condition resulting in delayed gastric emptying
- History of gastroparesis or other motility disorder
- Bowel ileus, bowel obstruction, or intra-abdominal process requiring surgery

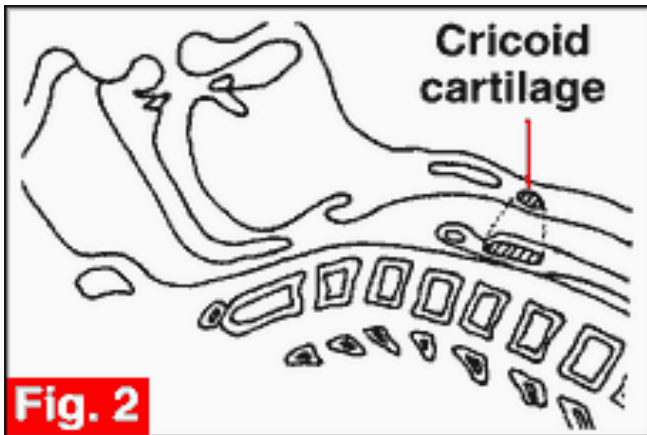


**Intubation in the Trauma Setting** Trauma patients may have an unclear or unstable cervical spine with spinal cord at risk of injury from atlanto-occipital (A-O) motion during laryngoscopy. In one airway management method frequently used in this setting, following anesthesia induction, one assistant maintains in-line stabilization (not traction) with the occiput held firmly to the backboard (hands are placed along the side of the head with fingertips on the mastoid holding the occiput down) while a second assistant applies cricoid pressure. The posterior portion of the cervical collar remains in place. Unfortunately, this arrangement limits attainment of the "sniffing" position and makes laryngoscopy more demanding. Fortunately, advanced airway devices like the Bullard laryngoscope or the GlideScope can be very helpful in intubating when the patient is not in the "sniffing" position (see [www.glidescope.net](http://www.glidescope.net)). One common alternative to this arrangement is awake fiberoptic intubation and awake positioning. Here, the patient is given general anesthesia only when positioned correctly and found to be neurologically intact. Source: [http://www.pharmacology2000.com/822\\_1/inline.jpg](http://www.pharmacology2000.com/822_1/inline.jpg)

**TABLE 8 - Steps in a Rapid Sequence Induction**

- Ensure that drugs, equipment and assistants are ready and that all patient monitors are operational.
- Remember that a rapid sequence induction is inappropriate in patients suspected to be difficult to intubate - awake intubation is preferable here.
- Generously preoxygenate the patient.
- Give induction drugs (e.g. thiopental 5 mg/kg and succinylcholine 2 mg/kg) in predetermined dose (do not titrate to clinical effect). At the same time have your assistant apply cricoid pressure to compress the esophagus (44 Newtons force, 10 lbs) [This is known as the "Sellick maneuver"].
- Do not ventilate while waiting for the drugs to work. (Note: some authorities advocate gentle mask positive pressure ventilation to reduce the chance of hypoxemia.)
- Intubate when conditions are correct; inflate ETT cuff.
- Ensure ETT is in correct position (clinically, capnograph).
- Have assistant relieve cricoid pressure.
- Continue with the remainder of the anesthetic.

**HISTORICAL DIVERSION** Franz Kuhn (1866-1929), a German surgeon, developed numerous inventions related to anesthesia, surgery and airway management. Kuhn was an important advocate of tracheal intubation, perfecting a flexo-metallic endotracheal tube design and different techniques of intubation. He also developed means of positive pressure ventilation to the lungs during thoracic surgery. Due to a dispute with Sauerbruch on the methods of avoiding a pneumothorax during thoracic surgery and the development of local and regional anaesthesia techniques, the value of his work and his revolutionary ideas were not appreciated until 40 years later. [Modified from Resuscitation. 2001;48:193-7.]




**Fig. 2**

When performing a rapid sequence induction, pressure on the cricoid (Sellick maneuver) results in occlusion of the esophagus, reducing the chance of regurgitation and aspiration. Of interest, recent MRI studies have called into question the effectiveness of this maneuver, but it is still the standard of care. Image source: [http://www.nda.ox.ac.uk/wfsa/html/u02/u02\\_b03.htm](http://www.nda.ox.ac.uk/wfsa/html/u02/u02_b03.htm)

**Some Types of Endotracheal Tubes (ETT)**

**Regular ETT**

For general use. Available in a variety of sizes and in uncuffed varieties for pediatric patients.



**MLT<sup>®</sup> Microlaryngeal Tracheal Tube**

A small diameter tube design with a regular sized cuff. Used in otolaryngology procedures, especially for surgery of the vocal cords or glottis.

**Endotrol<sup>®</sup> ETT**

Has a traction ring which moves the ETT tip anteriorly to facilitate blind nasotracheal intubation.

**Rae<sup>®</sup> ETT**

Low profile tube popular in head and neck surgery. Available in oral and nasal varieties.

**Sheridan Flexibend<sup>®</sup> ETT**

Another low profile tube for head and neck surgery.

**Reinforced (Armored) ETT**

Non-kinkable wire reinforced tube popular in head and neck surgery, neurosurgery, and surgery in the prone position.

**Double Lumen ETT**

For one-lung anesthesia for thoracic surgery and the like.

**Univent<sup>®</sup> ETT**

Contains a built-in inflatable bronchial blocker to allow occlusion either right or left of bronchus for one-lung anesthesia.

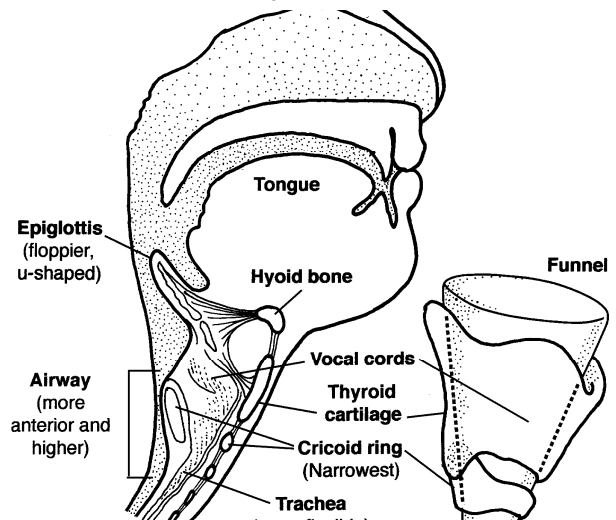
**Tracheostomy ETT**

For insertion into tracheostomy sites. Metal and plastic varieties. Cuffed and uncuffed varieties.

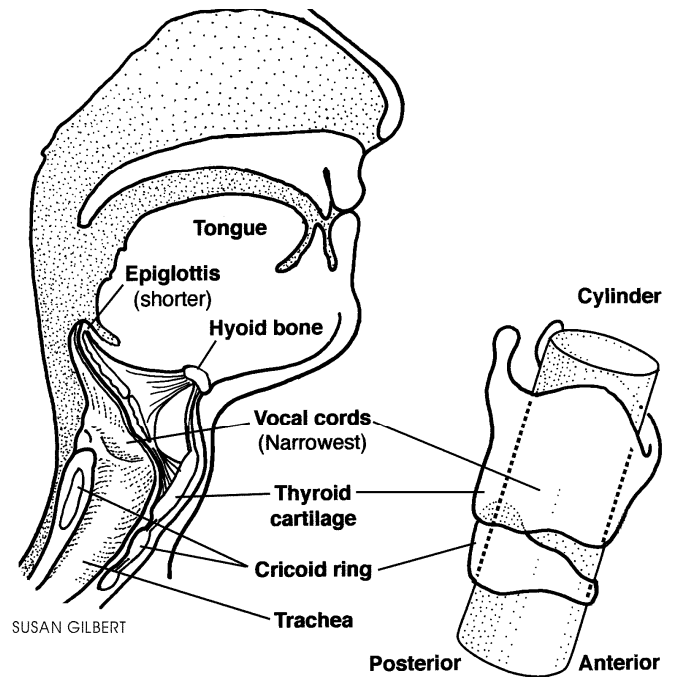
**Compared to the adult airway, the infant airway**

- is more anterior and higher
- has a floppier, U-shaped epiglottis
- is narrowest at the cricoid ring
- has a more "funnel-shaped" larynx
- has a more flexible trachea

**Pediatric Airway** <http://www.cpem.org/gif/26.gif>



**Adult Airway** <http://www.cpem.org/gif/27>



**Figure 3 Pediatric versus Adult Airway**

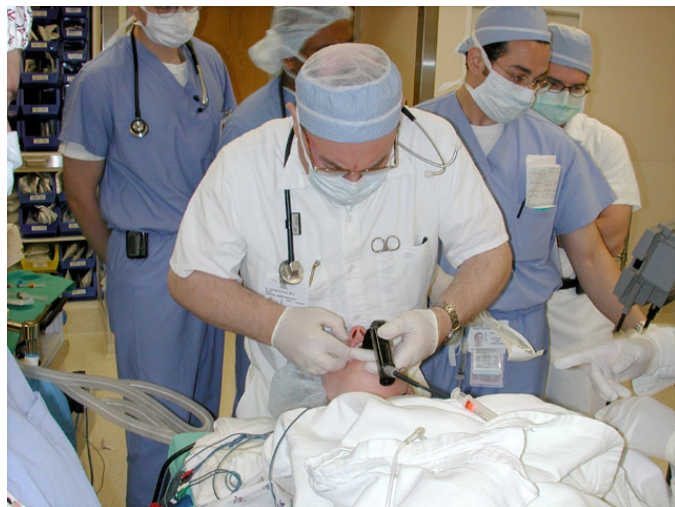## DIFFICULT AIRWAY EMERGENCY KIT

1. Rigid laryngoscope blades of alternate design and size from those routinely used; this may include a rigid fiberoptic laryngoscope (e.g., Bullard laryngoscope).
2. Tracheal tubes of assorted sizes.
3. Tracheal tube guides. Examples include (but are not limited to) semirigid stylets, ventilating tube changer, light wands, and forceps (e.g., McGill forceps) designed to manipulate the distal portion of the tracheal tube.
4. Laryngeal mask airways of assorted sizes; this may include the intubating laryngeal mask airway and the LMA-Proseal (LMA North America, Inc., San Diego, CA).
5. Flexible fiberoptic intubation equipment.
6. Retrograde intubation equipment. (e.g., kit from Cook)
7. At least one device suitable for emergency noninvasive airway ventilation. Examples include (but are not limited to) an esophageal tracheal combitube (Tyco Healthcare Nellcor Mallinckrodt, Pleasanton, CA, [www.combitube.org](http://www.combitube.org)), a hollow jet ventilation stylet and a transtracheal jet ventilator.
8. Equipment suitable for emergency invasive airway access (e.g., Melker cricothyrotomy kit from Cook).
9. An exhaled CO<sub>2</sub> detector.

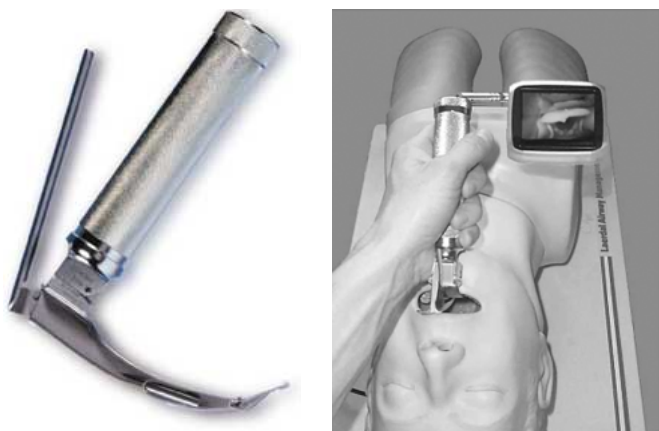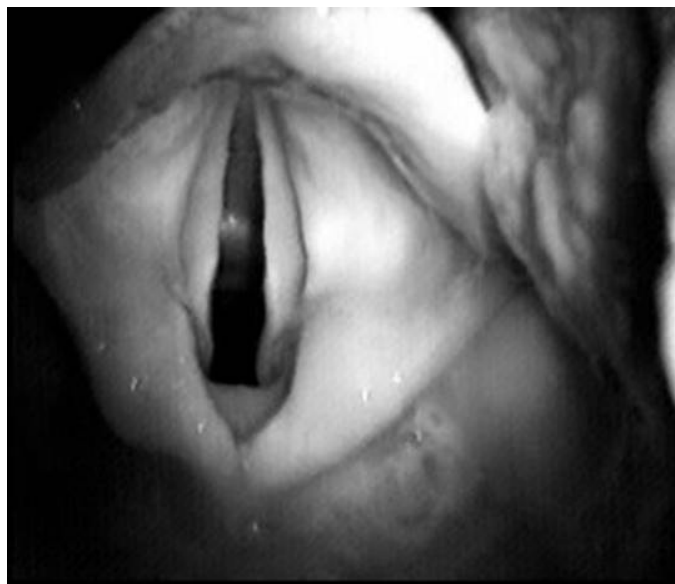
Some airway equipment for use in a readily available portable storage unit for use in airway emergencies. The specific items chosen will depend on specific needs and local conditions. Modified from *Anesthesiology*: Vol. 98 May 2003 pp 1269-1277. In addition to these suggestions, I would strongly recommend getting a GlideScope Video Laryngoscope ([www.glidescope.net](http://www.glidescope.net)).

## GlideScope Video Laryngoscope

The GlideScope® Video Laryngoscope is a novel system for laryngoscopy and tracheal intubation that utilizes a video camera embedded into a plastic laryngoscope blade. The blade is 18 mm wide at its maximum width (14 mm in newer models), and bends 60 degrees at the mid-line. This configuration was designed with the intent of providing a superior, unobstructed view to that obtained with a conventional laryngoscope. As shown in the figure below, the GlideScope is gently introduced into the oropharynx with the left hand in a manner similar to a regular laryngoscope. Attention is then directed to the video display, located to the right of this photograph, to obtain a good view of the glottis. For more information on the GlideScope as well as sample video clips, visit my Web site at [www.glidescope.net](http://www.glidescope.net)



**Top:** The author intubating a patient using the GlideScope. Note the video display is on the extreme right of the image.  
**Bottom:** Sample image obtained using the GlideScope.



**Left:** McCoy Laryngoscope with an articulating tip that can be used to lift a big epiglottis out of the way. Image credit: [http://www.penlon.com/images/fibreight\\_mccoy.jpg](http://www.penlon.com/images/fibreight_mccoy.jpg).

**Right:** The Thompson video laryngoscope (not yet commercially available) with a built-in video display  
Source: *Anaesthesia* 59 (4), 410-410.

**TABLE 9 - Popular Airway Blocks**

*These blocks are used primarily for awake intubation*

**Topical Anesthesia of the Airway** Administer about 5 ml of 4% lidocaine by nebulizer over 10-15 min. This is more effective after glycopyrrolate (e.g. 0.2 mg IV) dries the airway mucosa. While it provides anesthesia that is usually satisfactory for fiberoptic intubation, it is less effective with inflammation and secretions. Alternately, a variety of special atomizing devices are available for this purpose.

**Superior Laryngeal Nerve Block** The SLN block blocks sensation from the superior larynx above the cords. Inject 2 ml of 2% lidocaine just inferior to the greater cornu of the hyoid bone and superior to the thyroid cartilage.

**Transtracheal Topicalization** Topical anesthesia of tracheal mucosa below the cords may be achieved with 4 ml of 2% lidocaine through the cricothyroid membrane and allowing the patient to cough. Insert a 22 gauge intravenous catheter, remove the metal introducer, and aspirate air into a saline-filled syringe first to confirm placement (Fig 4).

**Glossopharyngeal (IX) Nerve Block** Blocks posterior third of tongue and tongue side of epiglottis. This intraoral block is best done after topical anesthesia of the tongue. The patient is asked to stick out his or her tongue and it is displaced laterally with a tongue blade. Place a 22 gauge, 9 cm (spinal) needle at the inferior portion of the posterior palatopharyngeal fold (tonsillar pillar) just deep to the mucosa. Aspirate prior to injection. Inject 2 ml of 2% lidocaine into the base of each anterior tonsillar pillar (palatoglossal arch). (This block is usually used only in those patients who retain active gag reflex after topicalization.)

### CAN VENTILATE, CAN'T INTUBATE

The following advice is offered for situations where the view at laryngoscopy suggests that intubation may be difficult, but for which the patient can be ventilated by mask while under anesthesia following induction doses of anesthetic agents.

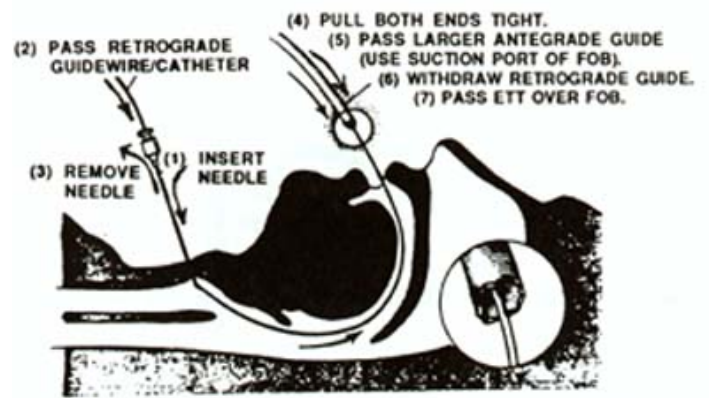
- Ensure help is available and pulse oximeter is in place before starting.
- Preoxygenate generously.
- Make sure head position is optimized ("sniffing position").
- Note the "grade" of view at laryngoscopy. (This will be needed when you write a note in the patient's chart about why the patient was difficult to intubate.)
- Ensure normocapnia and adequate depth of anesthesia between intubating attempts.
- Decide how to approach your second attempt. Would a larger blade (e.g., MAC 4) help? Would a straight blade (e.g., Miller) help? Would a McCoy blade help lift the epiglottis out of the way? Would a Gum Elastic Bougie help? Would external laryngeal manipulation help to move the larynx into a less anterior position?
- You are allowed one final third attempt. Wisdom may dictate that you give this chance to an experienced anesthesiologist should he or she drop by following your call for help. Alternately, you may choose to keep the patient asleep and use a special intubating technique like using a GlideScope video laryngoscope.

- If the patient can't be intubated after three tries, allow the patient to awaken and proceed with awake intubation using a FOB technique, or other method.
- Alternatives to consider: Trachlight; Gum Elastic Bougie (Echman stylet); Insert intubating LMA (Fastrach) and then an ETT via the intubating LMA (keeping the patient asleep); Insert an LMA ProSeal or a Combitube to allow application of high ventilatory pressures and to help prevent aspiration; Use a Syracuse-Patil face mask to facilitate fiberoptic intubation (keeping patient asleep); Retrograde intubation technique (see illustration below).

### REMEMBER TO CALL FOR HELP

**Illustration of retrograde intubation technique.**

<http://metrohealthanesthesia.com/images/retrograde2.jpg>



### Bail-Out" Algorithm CAN'T VENTILATE WELL, CAN'T INTUBATE (HAVE GIVEN UP ON INTUBATION)

**Use:** To awaken patient after failed intubation, where ventilation is difficult. This is a setting where you simply want the patient to wake up and breathe spontaneously.

1. Ensure that the patient is not in laryngospasm and that the patient's head and jaw are positioned properly. Call for help. Insert an airway of some kind
  - oral airway
  - nasopharyngeal airway
  - LMA (Laryngeal Mask Airway)
  - ILMA (Intubating LMA)
  - Combitube (especially with LMA placement failures)
  - Laryngeal tube

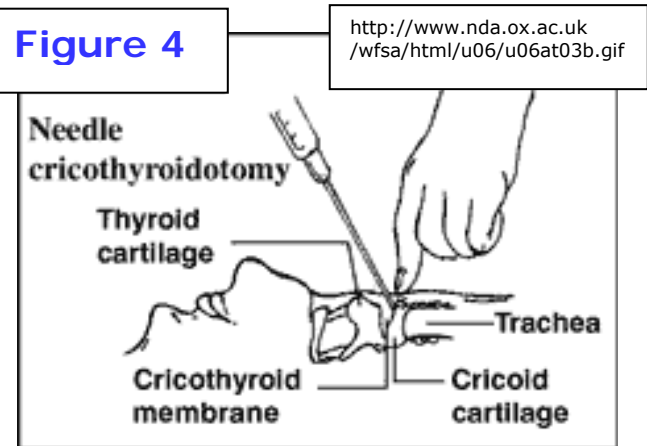
(WARNING: Airway insertion may lead to laryngospasm in lightly anesthetized patients.)
2. In some cases it will be helpful to utilize a two-person technique whereby one person manages the mask and holds the jaw in position using both hands ("jaw thrust maneuver"), while the other ventilates the patient by hand using the rebreathing bag and the emergency oxygen flush as needed.
3. As a last resort, a surgical airway (e.g., cricothyrotomy) or TTJV is sometimes needed (see next page).

### Transtacheal Jet Ventilation (TTJV)

In desperate circumstances where neither intubation nor ventilation is possible, injection of oxygen under high pressure (10-50 PSI) directly into the trachea can be life-saving. This is done by inserting a #14 gauge IV catheter or similar device through the cricothyroid membrane (Fig 4) and applying intermittent bursts of oxygen through this catheter. A nonkinkable catheter for TTJV is available from Cook. Complications of TTJV include barotrauma, pneumothorax, pneumo-mediastinum, pneumopericardium, subcutaneous emphysema, esophageal perforation and infection. Because of these concerns, many experts advocate the use of an emergency cricothyroidotomy kit (e.g., Melker) that uses ordinary ventilation pressures.

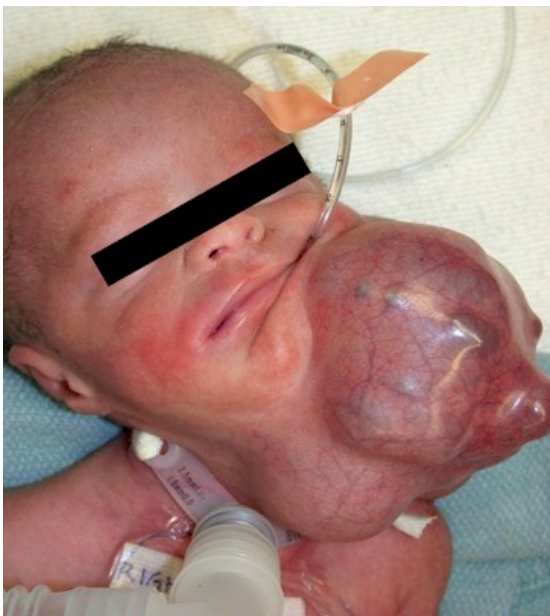

**Transtacheal Jet Ventilation (TTJV) Catheter (one version)**



**Below: Child with a tracheostomy to prevent airway obstruction from a cervical teratoma.**

Image credit: <http://bms.brown.edu/pedisurg/Brown/IBImages/Teratoma/Cervical%20Teratoma.html>



### Types of Surgical Airways

**Cricothyrotomy** – via incision through cricothyroid membrane, done using Seldinger technique (wire guide) or using a full incision. *[Used in emergency settings only]*

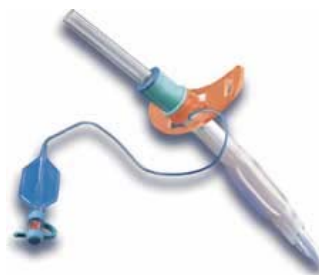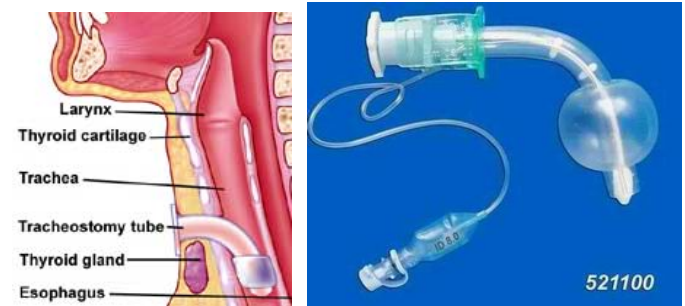
**Tracheostomy** – via incision through tracheal rings

### Indications for Tracheostomy

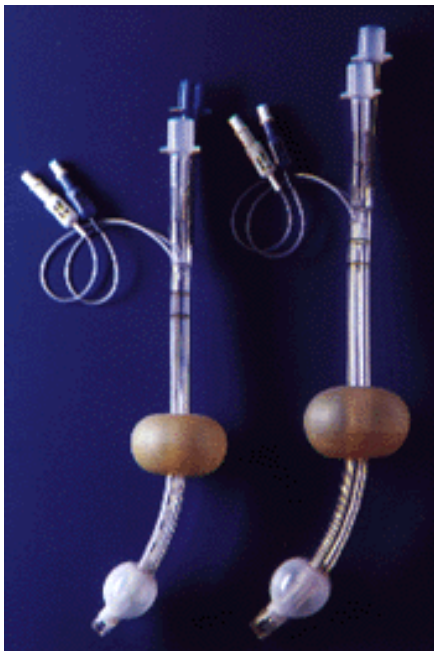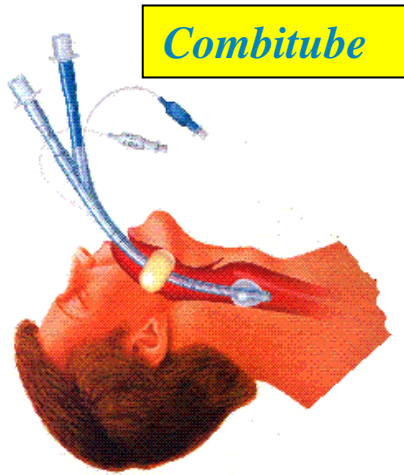
- Facilitate weaning from positive pressure ventilation
- To reduce the chance of tracheal stenosis
- Bypass an obstruction of the upper respiratory tract.
- Prevent aspiration from the pharynx or GI tract.
- Facilitate removal of secretions by suctioning
- Facilitate long-term airway management

### Precautions in Fresh Tracheostomy Patients

1. For the first week or so, all tube changes should be carried out in the operating room (OR) by an experienced surgeon, with good lighting and with a full set of surgical instruments (cricoid hooks, etc.). An anesthesiologist should also be present in case intubation "from above" needs to be attempted as a last resort if the surgeons lose the airway.
2. Once the tracheostomy site has begun to mature, it is no longer necessary to carry out tube changes in the OR, but a full set of tracheostomy instruments (especially cricoid hooks) should still be available. Changing the tube over a tube changer may also be useful, but some people find that it sometimes just unnecessarily complicates matters.
3. Obviously, before any tube change, the patient should be preoxygenated with 100% oxygen.
4. The fiberoptic bronchoscope (FOB) may be potentially useful in confirming tracheal placement of a tracheostomy tube prior to attempting positive pressure ventilation that could lead to subcutaneous emphysema if the tube is in fact malpositioned.



**Top left:** Anatomy of a tracheostomy. **Top right:** Typical cuffed tracheostomy tube allowing for positive pressure ventilation. **Bottom:** Portex tracheostomy tube designed for percutaneous placement using the Seldinger wire method and a series of dilators.



The Combitube is a double lumen tube with esophageal obturator lumen and tracheal lumen. The proximal (large) oropharyngeal balloon serves to seal off the mouth and nose, while the distal balloon (cuff) seals either the esophagus or trachea, depending on whether the distal end ends up in the esophagus (95% of the time) or the trachea (5% of the time). Studies so far suggest that aspiration does not occur and that high ventilatory pressures may be applied.

**Some Uses:**

- Emergency airway management - especially in prehospital patients and in the field
- Failed intubation; "Can't ventilate - can't intubate"
- Bleeding and vomiting patients
- Caesarian section (failed intubation)

**Contraindications:**

- Intact gag reflexes
- Esophageal pathology (e.g. esophageal varices)

For additional information visit [www.combitube.org](http://www.combitube.org)

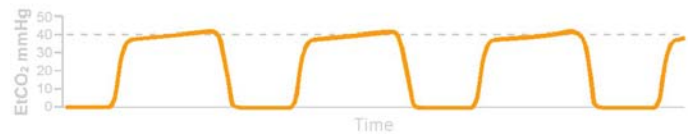**Capnography**

**Capnography** is the continuous analysis and recording of carbon dioxide CO<sub>2</sub> concentrations in respiratory gases. A capnograph uses one of two types of analyzers: mainstream or sidestream. Mainstream units insert a sampling window into the breathing circuit for gas measurement while sidestream units aspirate gas from the circuit and the analysis occurs away from the circuit. Capnographs may utilize infrared techniques (most common), mass spectroscopy, Raman scattering, or photoacoustic technology. Capnography is especially useful to monitor for a number important clinical situations:

- Verification of endotracheal intubation (a normal capnogram is not obtained when the endotracheal tube ends up in the esophagus.)
- Monitoring CO<sub>2</sub> elimination during cardiac arrest and CPR (the capnogram "improves" as pulmonary blood flow improves with adequate circulation).
- Detecting hypoventilation and hyperventilation
- Detecting rebreathing of CO<sub>2</sub> (in which case the inspiratory CO<sub>2</sub> level is nonzero).
- COPD patients (abnormal phase III capnogram)
- Inadequate seal of the endotracheal tube

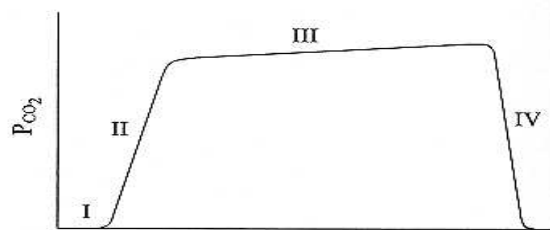
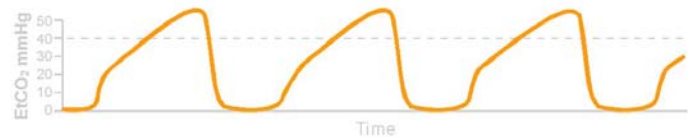
Note: A **sudden severe decrease in end-tidal CO<sub>2</sub>** is often due to a potentially catastrophic cardiorespiratory event: Circulatory arrest. Pulmonary embolus. Hypotension from severe blood loss. Compression of the IVC or SVC.

Additional information at <http://www.capnography.com>



**Normal Capnogram**

**Abnormal capnogram in a patient with severe COPD**



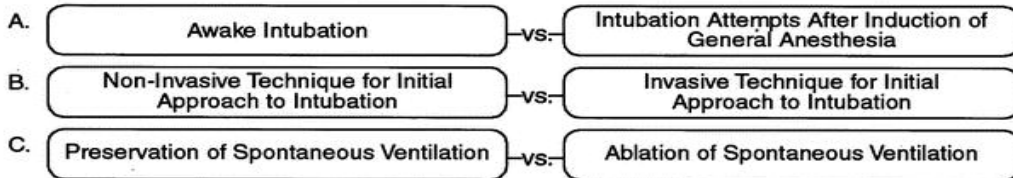
The capnogram has 4 segments that correspond to phases of the respiratory cycle. The first phase is a flat part, due to exhalation of dead space. The second is the ascending segment, from exhalation of mixed dead space and alveolar air. The third is the plateau portion that represents exhaled CO<sub>2</sub> from the alveoli. The fourth phase represents the beginning of inspiration.

Image credit: [www.rcjournal.com/contents/10.99/10991207fig3.jpg](http://www.rcjournal.com/contents/10.99/10991207fig3.jpg)

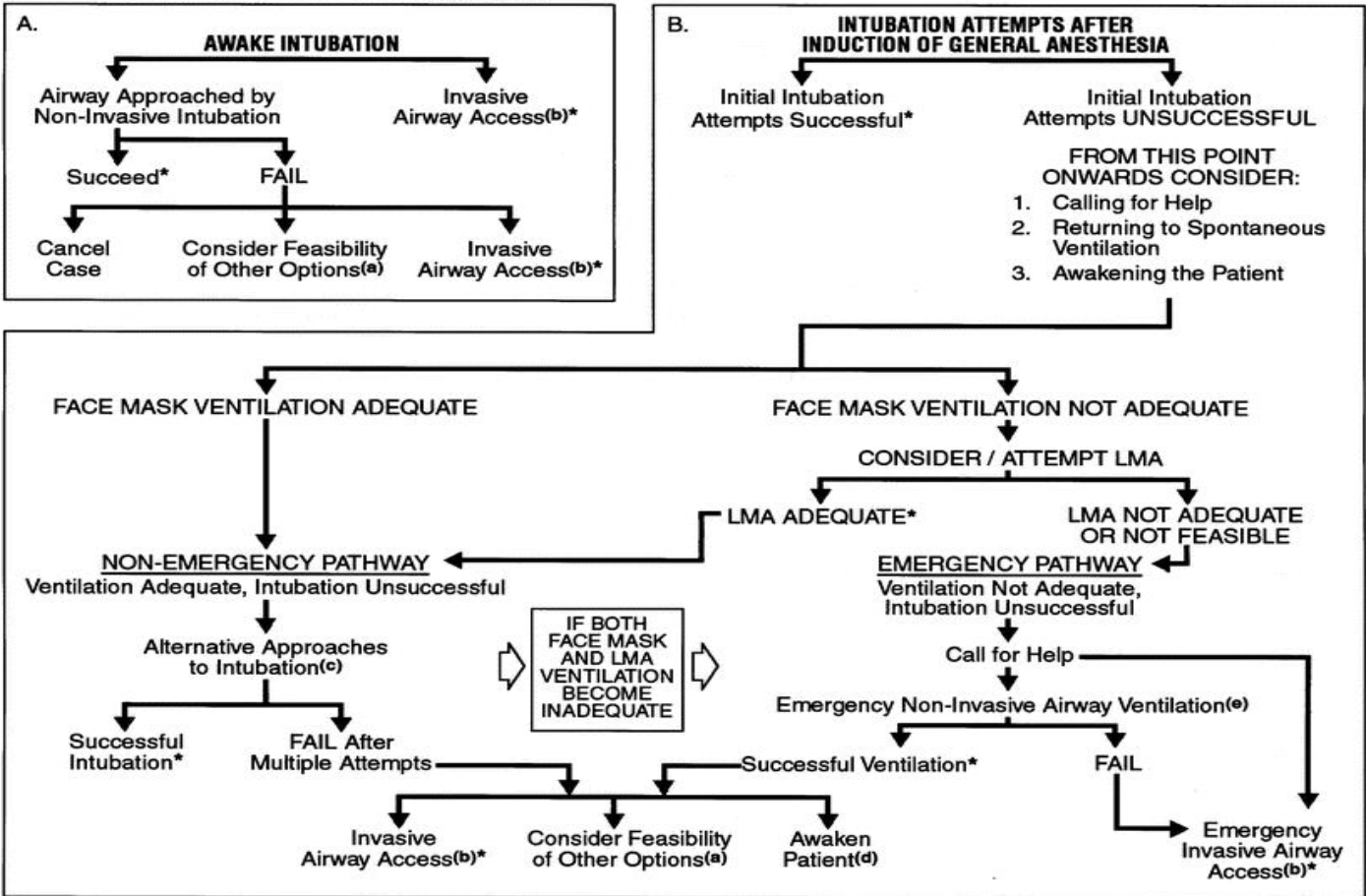


## DIFFICULT AIRWAY ALGORITHM

1. Assess the likelihood and clinical impact of basic management problems:
  - A. Difficult Ventilation
  - B. Difficult Intubation
  - C. Difficulty with Patient Cooperation or Consent
  - D. Difficult Tracheostomy
2. Actively pursue opportunities to deliver supplemental oxygen throughout the process of difficult airway management
3. Consider the relative merits and feasibility of basic management choices:



4. Develop primary and alternative strategies:



\* Confirm ventilation, tracheal intubation, or LMA placement with exhaled CO<sub>2</sub>

a. Other options include (but are not limited to): surgery utilizing face mask or LMA anesthesia, local anesthesia infiltration or regional nerve blockade. Pursuit of these options usually implies that mask ventilation will not be problematic. Therefore, these options may be of limited value if this step in the algorithm has been reached via the Emergency Pathway.

b. Invasive airway access includes surgical or percutaneous tracheostomy or cricothyrotomy.

c. Alternative non-invasive approaches to difficult intubation include (but are not limited to): use of different laryngoscope blades, LMA as an intubation conduit (with or without fiberoptic guidance), fiberoptic intubation, intubating stylet or tube changer, light wand, retrograde intubation, and blind oral or nasal intubation.

d. Consider re-preparation of the patient for awake intubation or canceling surgery.

e. Options for emergency non-invasive airway ventilation include (but are not limited to): rigid bronchoscope, esophageal-tracheal combitube ventilation, or transtracheal jet ventilation.

**Figure 6.** Algorithm for managing the patient with a difficult airway, developed by the American Society of Anesthesiologists. (Source: American Society of Anesthesiologists Task Force on Management of the Difficult Airway. Practice guidelines for management of the difficult airway: an updated report by the American Society of Anesthesiologists Task Force on Management of the Difficult Airway. *Anesthesiology*. 98(5):1269-77, May 2003) AVAILABLE FREE ONLINE AT [www.anesthesiology.org](http://www.anesthesiology.org)

**Fiberoptic Intubation** Tracheal intubation is often performed using a flexible fiberoptic bronchoscope when the glottis cannot be readily visualized by conventional means (e.g. using Macintosh or Miller blades). It is usually performed awake via the nasal or oral routes using topical anesthesia with a drying agent such as glycopyrrolate administered to prevent secretions from washing away the topical anesthesia and obscuring the view. Superior laryngeal and glossopharyngeal nerve blocks as well as transtracheal anesthesia are potentially helpful, although many practitioners use the "spray anesthesia as you go" method. Mild sedation is often administered concurrently. The principal advantage of fiberoptic intubation is that it is a safe and (in well trained hands) quite tolerable means of inspecting and securing a difficult airway in an awake patient. Disadvantages include the expense of the scope, the need for special cleaning and the need for clinical experience in the technique. For a nice Web site dealing with this topic, visit <http://faculty.washington.edu/pcolley/>

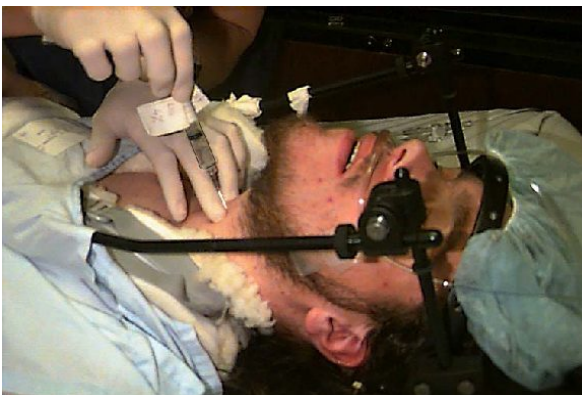

Superior laryngeal and glossopharyngeal nerve blocks as well as transtracheal anesthesia are potentially helpful, although many practitioners use the "spray anesthesia as you go" method. Mild sedation is often administered concurrently. The principal advantage of fiberoptic intubation is that it is a safe and (in well trained hands) quite tolerable means of inspecting and securing a difficult airway in an awake patient. Disadvantages include the expense of the scope, the need for special cleaning and the need for clinical experience in the technique. For a nice Web site dealing with this topic, visit <http://faculty.washington.edu/pcolley/>

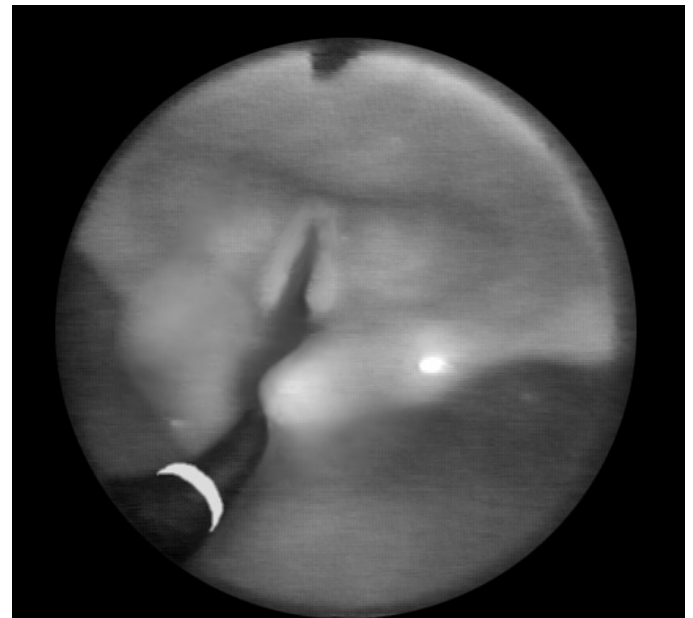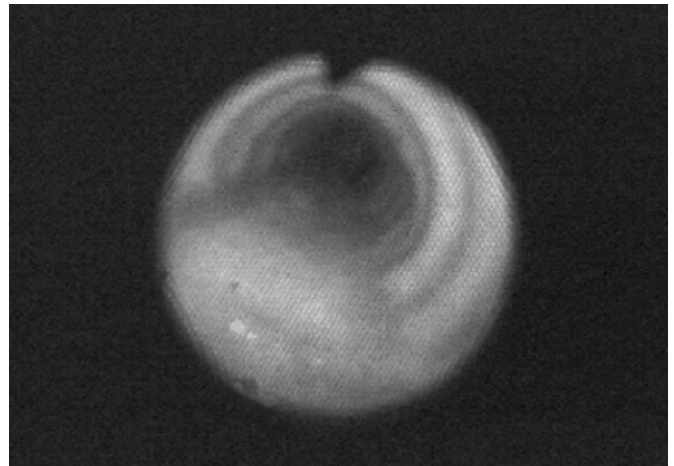
### POSSIBLE INDICATIONS FOR FIBEROPTIC ENDOSCOPY/FIBEROPTIC INTUBATION

- a) **Difficult airway**
  - Fixed neck (e.g. ankylosing spondylitis)
  - Neck masses and hematomas
  - Airway infections (e.g. Ludwig's angina)
  - Mandibular hypoplasia
  - Congenital syndromes
  - Facial trauma
  - Laryngeal and pharyngeal tumors
  - Radiation to neck post cancer surgery
- b) **Neck movement not desirable**
  - Unstable or uncleared C-spine
  - Vertebrobasilar insufficiency
- c) **High risk of dental damage**
- d) **Extubation trial**
- e) **ETT problems (single and double lumen)**
- f) **Upper/Lower airway endoscopy**
  - Airway burns and inhalation injury
  - Masses and hematomas causing tracheal compression
  - Examining airways for aspiration, compression or foreign bodies

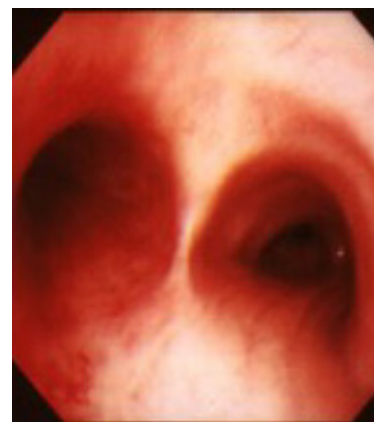
**Transtracheal Anesthesia** Patients with cervical spine injuries are often placed in a halo apparatus to stabilize the spine and reduce the chances of cord injury. When these patients undergo surgery, fiberoptic awake intubation with topicalization of the airway is usually chosen. This young man is having a transtracheal injection of local anesthesia through the cricothyroid membrane.



**Bronchoscopic view of the adult trachea** The cartilaginous, C-shaped tracheal rings are seen anteriorly, and the membranous portion, overlying the esophagus, is posterior. From *Barash Clinical Anesthesia 2001*



View of a fiberoptic bronchoscope passing through a patient's vocal cords. <http://faculty.washington.edu/pcolley/2BW.jpg>



View of the carina through a fiberoptic bronchoscope. The left and right main bronchi are readily seen. The carina resides approximately at the T4-T5 level, and is approximately at the same level as the sternal notch. Depending upon a person's size, the carina is about 30 cm from the teeth, measured along the path of the airway.



## Laryngeal Mask Airway

While the endotracheal tube (ETT) has served a preeminent role in airway management, use of the laryngeal mask airway (LMA), is becoming popular, especially in outpatient surgery, and in the management of airway crises. The LMA is designed to provide an "oval seal around the laryngeal inlet" once the LMA is inserted and the cuff inflated. When inserted, it lies "at the crossroads of the digestive and respiratory tracts". The LMA is particularly useful where a mask fit is difficult, e.g., in bearded or edentulous patients or where both hands of the clinician need to be free. Patients need not necessarily be breathing spontaneously for the LMA to be of use; provided the patient has normal lungs and normal laryngeal anatomy (and a properly sized mask), positive pressure ventilation can be used. However, when peak airway pressures exceed 20 cm H<sub>2</sub>O, gas leaks around the cuff are more likely.

**Difficult Airways** The role of the LMA in patients who are suspected to be difficult to intubate is controversial. While some (perhaps most) authorities would emphasize awake intubation in such cases, others would consider carrying out attempted laryngoscopy after induction, with LMA placement if ETT placement is unsuccessful. Still others would recommend going directly with the LMA, avoiding laryngoscopy and attempted intubation.

**LMA Insertion** The deflated, lubricated LMA is best inserted under propofol anesthesia with the head and neck positioned as for normal intubation. With an assistant temporarily holding the mouth open until the widest part of the mask is past the teeth, or using the third finger of the inserting hand, the tip of the LMA is inserted into the mouth, pressing the tip against the hard palate as it is advanced cephalad into the pharynx with the right hand. Then, with the index finger positioned at the cuff/tube interface, the LMA is inserted as far as possible into the hypopharynx. Before removing the index finger, bring the other hand up to the connector and press gently but firmly in the cephalad direction. When resistance is felt, the tip of the cuff is positioned at the upper esophageal sphincter. After assuring that the black line on the LMA is facing the upper lip, the cuff is inflated.

### Some situations where the LMA may be useful

- Fasted patients for short surgical cases not needing muscle relaxation & with little risk of regurgitation
- Difficult mask fit (beards, edentulous)
- Need for free hands
- Special situations
  - Opera singers/rock stars/public speakers
  - Thyroid surgery (to check RLN function)
  - Difficult airway rescues

### Potential contraindications to using the LMA

*Not all contraindications are absolute.*

- Full stomach/aspiration risk (including hiatus hernia)
- Clinician untrained in LMA use
- Patients in the prone position
- Morbidly obese patients
- Oropharyngeal pathology expected to result in a poor LMA fit (e.g., radiotherapy for hypopharynx/larynx)
- Pharyngeal/glottic surgery (tonsillectomy OK)
- Need for PPV with peak airway pressures > 20 cm H<sub>2</sub>O (stiff lungs, Trendelenburg pos'n, laparoscopy)
  - [However, the LMA ProSeal is specifically designed to allow for PPV with much higher airway pressures].*
- Very long cases

## Laryngeal Mask Airway Sizes

Size	Weight	Maximum air in cuff
1	under 5 kg	4 ml
1.5	5 to 10 kg	7 ml
2	10 to 20 kg	10 ml
2.5	20 to 30 kg	14 ml
3	30 kg to small adult	20 ml
4	adult	30 ml
5	big adult/poor seal with 4	40 ml

## Laryngeal Mask Types

	<p><b>LMA   Classic™</b> Reusable airway device made primarily of medical-grade silicone rubber. All LMAs are designed to conform to the contours of the hypopharynx with the LMA lumen facing the laryngeal opening.</p>
	<p><b>LMA   Unique™</b> Single-use disposable version of the LMA Classic™. Because it is disposable, it is well suited for areas where stocking a reusable device is not practical or economical.</p>
	<p><b>LMA   Flexible™</b> This LMA has a wire-reinforced, flexible shaft that is particularly useful when the surgeon and anesthesiologist are competing for access, such as procedures involving the head or neck.</p>
	<p><b>LMA   ProSeal™</b> Provides higher airway seal pressures for use with positive pressure ventilation (PPV). A "drain tube" separates the respiratory and GI tracts. The maximum airway seal is about 10 cm H<sub>2</sub>O higher than the LMA Classic™ - up to 30 cm H<sub>2</sub>O.</p>
	<p><b>LMA   Fastrach™</b> The Fastrach™ is designed to allow blind or FOB assisted intubation while allowing the patient to be ventilated in the meantime. It is particularly useful in anticipated and unanticipated difficult airway situations. It is best used in conjunction with a special reusable silicone ETT.</p>

### Extubation Criteria

(From Barash's Clinical Anesthesia, 2001)

#### Subjective Clinical Criteria:

Follows commands  
Clear oropharynx/hypopharynx (e.g., no active bleeding, secretions cleared)  
Intact gag reflex  
Sustained head lift for 5 seconds, sustained hand grasp  
Adequate pain control  
Minimal end expiratory concentration of inhaled anesthetics

#### Objective Criteria:

Vital Capacity:  $\geq 10$  ml/kg  
Peak voluntary negative inspiratory pressure:  $> 20$  cm H<sub>2</sub>O  
Tidal Volume  $> 6$  cc/kg  
Sustained tetanic contraction (5 sec)  
T<sub>1</sub>/T<sub>4</sub> ratio  $> 0.7$   
Alveolar-Arterial Pao<sub>2</sub> gradient (on FiO<sub>2</sub> of 1.0):  $< 350$  mm Hg\*  
Dead Space to Tidal Volume ratio:  $\leq 0.6$ \*

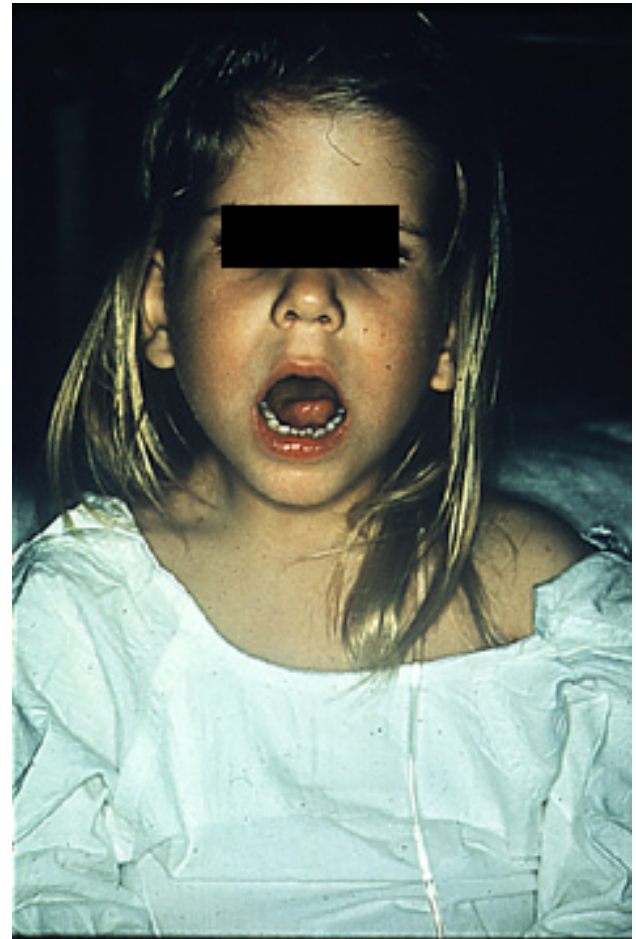\*Used during weaning from mechanical ventilation in the intensive care setting.

**Difficult Extubation** Extubation is the process of removing an endotracheal tube (ETT) from the patient's trachea. This should ordinarily only be done with the patient awake and obeying verbal commands. Even so, catastrophes following extubation can occur, such as total collapse of the airway in a patient with tracheomalacia. Sometimes it is wise to extubate over an ETT exchange catheter (see image below), such as any patient who would be very difficult to reintubate. Such a device can be left in place and later used to facilitate reintubation should a trial of extubation end in failure. If reintubation becomes necessary the exchange catheter can then be used as a guide to direct the new ETT through the cords. Some exchange catheters can also be used to administer low flow oxygen deep into the lungs (e.g. 2-4 liters/min flow rate) as well as for capnography or even emergency jet ventilation in a manner similar to TTJV (see information on ETT Exchange Catheters from Cook ([www.cookcriticalcare.com](http://www.cookcriticalcare.com))).

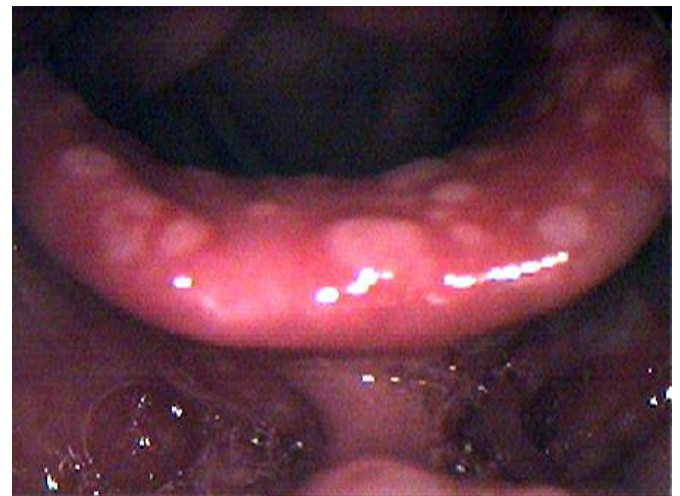Patients may be at high risk at extubation either because of an inability to tolerate extubation or because of potential difficulties in reestablishing the airway. Examples of the former include tracheomalacia, vocal cord palsy, bilateral recurrent laryngeal nerve injury etc. Difficulty reestablishing the airway may occur with major head or neck surgery, previous intubation difficulties, maxillomandibular fixation and many other causes. **BELOW: Tube Exchanger from Cook, with the distal end on top, and the proximal end below.**



### Epiglottitis Images



Child with epiglottitis positioned leaning forward and drooling. (<http://www.sickkids.on.ca/otolaryngology/EducationalMaterial/airway/images/019.jpg>)



Edematous, reddened epiglottitis. Also known as supraglottitis, epiglottitis is acute, severe, and life-threatening. Its spectrum has changed with the introduction of the *Haemophilus influenzae* type B (HIB) vaccine in 1985. Previously it occurred most frequently as a result of HIB in kids aged 2-7. (<http://www.otolaryngologie.cz/pictures/otoskopie/epiglottitis.jpg>)

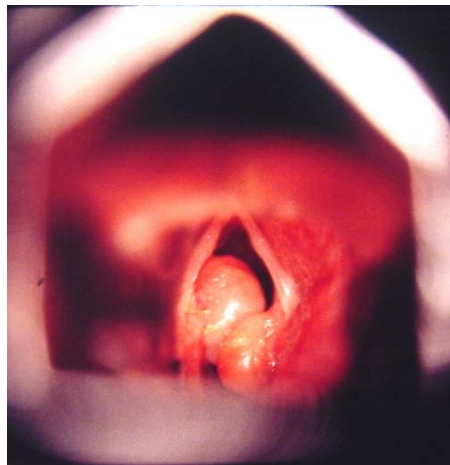
### Medical Conditions with Airway Implications

**Obesity** The obese patient has a reduced functional residual capacity (FRC) with reduced pulmonary oxygen stores, leading to rapid desaturation when apnea occurs. Obese patients with a short thick neck, a large tongue and/or redundant folds of oropharyngeal tissue may be difficult to intubate and are at increased risk to develop airway obstruction. Positive pressure ventilation may be more difficult in these patients because of decreased chest wall compliance (restrictive lung defect). The increased work of breathing associated with obesity leads patients to take smaller tidal volumes and breathe at an increased respiratory rate, leading to atelectasis, ventilation/perfusion mismatching, and increased degrees of airway closure. Should a surgical airway become necessary, the situation is made much more difficult as the surgeon attempts to identify the trachea deep in a mound of adipose tissue. Finally, very obese patients are at increased risk of regurgitation/aspiration both because of increased intraabdominal pressure and the high incidence of having large gastric fluid volumes.

**Diabetes and the Airway** About one third of long term type diabetics (juvenile onset) will present with laryngoscopic difficulties. This is due in part to diabetic "stiff joint syndrome" characterized by short stature, joint rigidity, and tight, waxy skin. The fourth and fifth proximal pharyngeal joints are most commonly involved. Patients with diabetic stiff joint syndrome have difficulty in approximating their palms and cannot bend their fingers backward ("prayer sign"). When the cervical spine is involved, limited atlanto-occipital joint motion may make laryngoscopy quite difficult. Glycosylation of tissue proteins from chronic hyperglycemia and abnormal cross-linking of collagen is believed to be responsible.

**Rheumatoid Arthritis** Rheumatoid arthritis (RA) is a multisystem autoimmune disease with many anesthetic implications. Patients with RA may challenge the anesthesiologist because of cervical spine instability. In addition, temporomandibular joint (TMJ) or cricoarytenoid joint immobility may limit safe access to the airway. The preoperative anesthetic assessment must focus on possible airway difficulties. Patients must be questioned and examined to elicit evidence of neck pain, limitation of cervical spine movement, nerve root impingement or spinal cord compression. Lateral C-spine flexion-extension X-rays are potentially helpful in patients with cervical spine symptomatology to assess the possibility of cervical spine subluxation. The need for these X-rays in completely asymptomatic patients remains controversial; however, one should keep in mind case reports of neurological damage following direct laryngoscopy and intubation in asymptomatic patients. Patients with cervical spine instability are often intubated and positioned awake before surgery to avoid neurological injury. The TMJs must be examined to ensure that mouth opening and anterior subluxation of the mandible will permit direct laryngoscopy. Patients demonstrating stridor or hoarseness may require awake direct or indirect laryngoscopy to assess the possibility of arytenoid involvement and determine the size of the glottic opening. Finally, the larynx may be displaced and twisted from its usual location by erosion and collapse of cervical vertebrae.

**Thyroid Goiter** Large thyroid goiters can lead to compression of the trachea and even tracheomalacia. This can worsen in the supine position and with the induction of general anesthesia. Retrosternal extensions of large goiters may act as mediastinal masses. Rarely, thyroid goiter may present as a oropharyngeal mass or cause bilateral recurrent nerve paralysis.

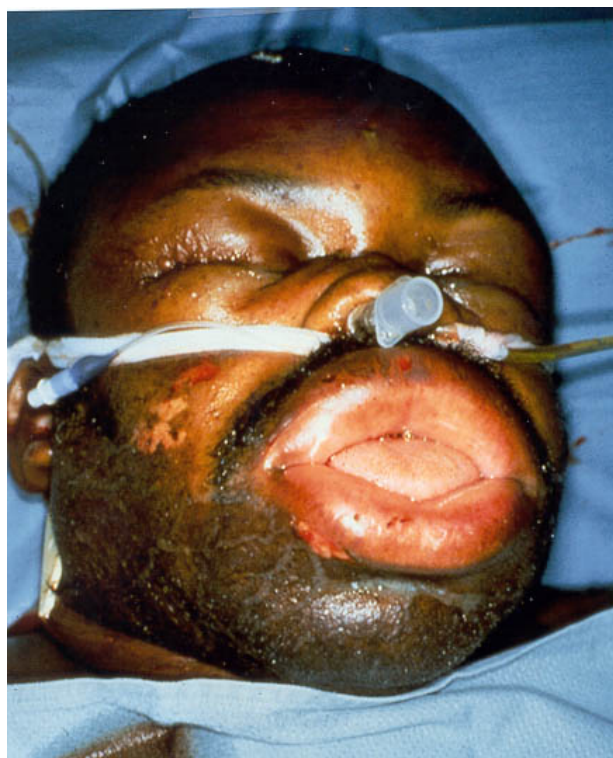

#### Postintubation granuloma of the larynx.

Granulomas of the larynx can occur from a variety of causes, such as reflux, extensive singing or "voice abuse". Postintubation granuloma of the larynx is now a well recognized entity, which has increased in frequency because of the common use of

intubation for general anesthesia. Voice rest, corticosteroids, and microsurgical removal are common therapies, although some cases have a high rate of recurrence. The granuloma is often associated with progressive hoarseness and can result in dyspnea and even complete airway obstruction.

(<http://www.ghorayeb.com/files/IntubationGranulomaGG1.jpg>)



#### Burn Victim with Nasal Endotracheal Tube (ETT).

This patient would likely be very difficult to intubate orally using a regular laryngoscope (note the very enlarged tongue). Image credit: [www.burnsurgery.org/Modules/initial/images/page\\_19b.jpg](http://www.burnsurgery.org/Modules/initial/images/page_19b.jpg)

**Did you know ...** The main cause of fire-related death is smoke inhalation. About 50-80% of fire deaths are the result of smoke inhalation rather than burns. Heat injures the airway mucosa, resulting in edema, erythema, and ulceration. However, edema sufficient to impair upper airway patency may not occur until 12 to 18 hours later, just when you thought that the airway was OK.

**Stridor** Stridor, or noisy inspiration from turbulent gas flow in the upper airway, is often seen in airway obstruction, and always commands attention. Wherever possible, attempts should be made to immediately establish the cause of the stridor (e.g., foreign body, vocal cord edema, tracheal compression by tumor, functional laryngeal dyskinesia, etc.) The first issue of clinical concern in the setting is stridor whether or not intubation is immediately necessary. If intubation can be delayed for a period a number of potential options can be considered, depending on the severity of the situation and other clinical details. These include:

- use of Heliox (70% helium, 30% oxygen)
- expectant management with full monitoring, oxygen by face mask, and positioning the head of the bed for optimum conditions (e.g., 45 - 90 degrees)
- use of nebulized racemic epinephrine (0.5 ml of 2.25% in 2.5 ml saline) or nebulized cocaine 2-3 mg/kg (but not both, because epinephrine combined with cocaine predisposes the patient to ventricular arrhythmias) in cases where airway edema may be the cause of the stridor
- use of dexamethasone (Decadron®) 4-8 mg IV q 8 - 12 h in cases where airway edema may be the cause of the stridor

**Laryngospasm** Laryngospasm is the protective reflex closure of the upper airway from spasm of the glottic musculature. This form of airway obstruction is especially common in children and is associated with light planes of anesthesia and the presence of foreign matter (e.g. blood or secretions) irritating the vocal cords. While laryngospasm can often be broken by deepening the level of anesthesia with IV propofol or other IV agent, sometimes muscle relaxation (e.g. with succinylcholine 10-20 mg IV) is needed to allow the patient to be ventilated. Failure to deal with laryngospasm can result in significant periods where the patient cannot be adequately ventilated, resulting in hypoxemia and hypercarbia. Some patients who are able to generate very large negative inspiratory pressures in attempting to breath against the obstruction may succumb to "negative-pressure pulmonary edema". A proactive approach to preventing / terminating laryngospasm and preventing hypoxemia and other complications is the mark of a seasoned anesthesiologist.

**More Airway Problems**

Modified from [www.nda.ox.ac.uk/wfsa/html/u15/u1517\\_01.htm](http://www.nda.ox.ac.uk/wfsa/html/u15/u1517_01.htm)

<ul style="list-style-type: none"> <li>• <b>High Airway Pressure</b> <ul style="list-style-type: none"> <li>- Misplaced, blocked or kinked airway/ETT</li> <li>- Narrow bore ETT (e.g. MLT)</li> <li>- Pneumoperitoneum</li> <li>- Trendelenburg position</li> <li>- Bronchospasm</li> <li>- Tension pneumothorax</li> <li>- Hemothorax</li> <li>- Sticking valve</li> <li>- Morbid obesity</li> </ul> </li> <li>• <b>Wheezing</b> <ul style="list-style-type: none"> <li>- Bronchospasm</li> <li>- Pneumothorax</li> <li>- Anaphylaxis</li> </ul> </li> </ul>	<ul style="list-style-type: none"> <li>• <b>Desaturation</b> <ul style="list-style-type: none"> <li>- Endobronchial ETT</li> <li>- Atelectasis</li> <li>- Pneumothorax</li> <li>- Oxygen supply or delivery failure</li> <li>- Poor ventilation</li> <li>- Poor perfusion / artefact</li> </ul> </li> <li>• <b>Abnormal Capnogram</b> <ul style="list-style-type: none"> <li>- Ventilator problem</li> <li>- Circuit problem</li> <li>- Circulatory problem</li> <li>- Air embolism</li> <li>- Artefact</li> </ul> </li> <li>• <b>Low airway pressure</b> <ul style="list-style-type: none"> <li>- Where is the leak?</li> </ul> </li> </ul>
--	--

**Above:** You should have precompiled (memorized) approaches to dealing with these important clinical problems and their possible causes. A systematic approach: machine problem, ETT problem, patient problem (bronchi, alveoli, pleural space) can be very useful in dealing with many of these issues.

**Epiglottitis** Epiglottitis is among the most dreaded of airway infections, especially in children. Victims are often age 2 to 6, infected with H. flu. and tend to be systemically ill ("toxic") often with a fever and/or often sitting up in a "tripod" position and drooling because of difficulty with swallowing. (Fortunately, pediatric epiglottitis has become much less common because of the H. flu. vaccine.) Examining the child's airway may exacerbate the problem (by increasing airway edema) so tongue depressors and laryngoscopy are not ideal options in the initial management. Anything that might bring the child to cry (for example, needles) should generally be avoided. The usual approach to management involves a careful inhalational induction with the child sitting in the anesthetist's lap and intubation of the child while he or she is breathing spontaneously under deep sevoflurane anesthesia. If at laryngoscopy the orifice through the epiglottis can't be identified, one trick is to have someone compress the child's chest, thus generating a small bubble in the epiglottis that the intubator can aim for. Epiglottitis can occur in adults too (George Washington is said to have died of it – see the historical note elsewhere in this work) but the situation is less dreadful here because the adult airway is larger. Most people would use awake fiberoptic bronchoscopy to secure the airway in this situation. There is growing experience with conservative management of adult epiglottitis (admission to an ICU for intravenous antibiotic therapy and with avoidance of intubation).

**Ludwig's Angina** Ludwig's angina is a multispace infection of the floor of the mouth. The infection usually starts with infected mandibular molars and spreads to sublingual, submental, buccal and submandibular spaces. The tongue becomes elevated and displaced posteriorly, which may lead to loss of the airway, especially when the patient is placed in the supine position. An additional concern is the potential for abscess rupture into the hypopharynx (with possible lung soiling) either spontaneously or with attempts at laryngoscopy and intubation. Airway management options will depend on clinical severity, surgical preferences, and other factors (e.g. radiographic findings). While elective tracheostomy prior to incision and drainage remains the classical treatment modality, many experts advocate awake fiberoptic intubation if at all possible.

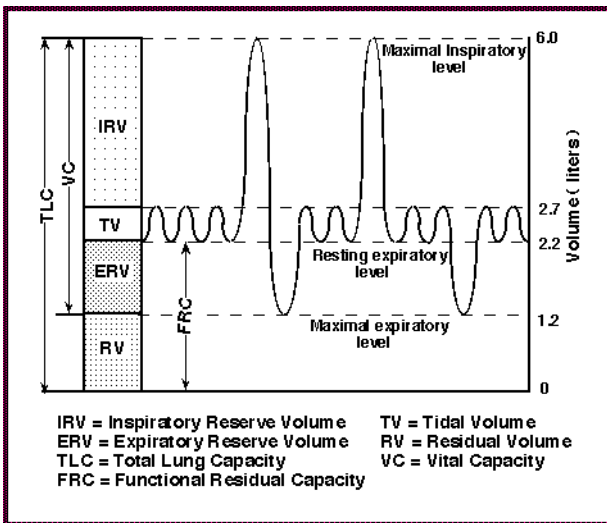
**Retropharyngeal Abscess** Retropharyngeal abscess formation may occur from bacterial infection of the retropharyngeal space secondary to a tonsillar or dental infections. Untreated, the posterior pharyngeal wall may advance anteriorly into the oropharynx, resulting in a dyspnea and airway obstruction. Other clinical findings may include difficulty in swallowing, trismus and a fluctuant posterior pharyngeal mass. An abscess cavity may be evident on lateral neck x-rays with anterior displacement of the esophagus and upper pharynx. Airway management may be complicated by trismus or airway obstruction. Because abscess rupture can lead to soiling of the trachea, contact with the posterior pharyngeal wall during laryngoscopy and intubation should be minimized. Incision and drainage is the mainstay of treatment. Tracheostomy is often, but not always required.

**Anaphylaxis** During anaphylactic (or anaphylactoid) reactions, massive release of histamine and other noxious substances from mast cells and basophils produce "leaky capillaries" which result in interstitial fluid buildup (edema). When significant edema of any portion of the airway results, respiratory obstruction can occur. Airway-related clinical manifestations may include dyspnea, stridor and facial edema. Erythema, urticaria, bronchospasm and hypotension may also be present. While older textbooks have advocated establishing a surgical airway, early intubation is now recommended if the airway appears to be at risk. Another airway-related problem which may occur in anaphylaxis is bronchospasm, sometimes with sufficient severity that air entry is so poor that wheezing is not present and ventilation may be next to impossible. As always, the primary drug treatment in life-threatening anaphylaxis is epinephrine (2-4 mcg/kg), administered either intravenously (ideally), subcutaneously, or intramuscularly and repeated at 5 - 10 minute intervals based on the patient's clinical response.

**Airway Aphorisms: Random Insights into the World of Clinical Airway Management**

- Superior judgment always trumps superior skill when tackling difficult airway problems.
- Have a precompiled plan for use when clinical airway difficulties are encountered.
- The awake airway is the safest airway.
- Spontaneous breathing is generally safer than paralysis with positive pressure ventilation by mask, especially in cases of airway obstruction.
- Have a low threshold for waking up the elective patient you are having trouble intubating.
- Clinical ego is the patient's enemy ... know when to back off and when to call for help.
- By all means, call for help with airway emergencies. But don't let him or her kill your patient by trying another series of intubation attempts instead of letting you wake up the patient.
- Drugs that last a long time discourage graceful recovery to a safe airway situation.
- A surgical airway is better than an arrested patient with a nice-looking neck.
- In real life emergency surgical airways are usually a bloody mess.
- The very obese patient presents special airway challenges.
- Pregnant patients, even when not in the least obese, often behave like obese patients from the perspective of airway management.
- If you never use the laryngeal mask airway (LMA) in elective cases, you'll definitely not be elegant and slick when you try to use it in an emergency.
- Fiberoptic intubation is usually ill-advised in dire emergency cases, even with experience. This is especially true with an edematous, bloody airway.

**LUNG VOLUMES AND CAPACITIES (Spirometry)**



From <http://hyperphysics.phy-astr.gsu.edu/hbase/kinetic/idegas.html>

**Ideal Gas Law:  $PV = nRT = NkT$**

- $n$  = number of moles
- $R$  = universal gas constant = 8.3145 J/mol K
- $N$  = number of molecules
- $k$  = Boltzmann constant =  $1.38066 \times 10^{-23}$  J/K
- $k = R/N_A$  where
- $N_A$  = Avogadro's number =  $6.0221 \times 10^{23}$

**GAS LAWS**

Notation: P = pressure (mm Hg) V = volume (mL) T = temperature (Kelvin) [273 Kelvin = 0 Celsius]

**BOYLE'S LAW**  $P \times V = \text{constant}$  (at constant T)  
 That is, P is proportional to 1/V. Gases do not obey Boyle's law at temperatures approaching their point of liquefaction. Boyle's law concerns perfect gases and is not obeyed by real gases over a wide range of pressures. At infinitely low pressures all gases obey Boyle's law. Boyle's law does not apply to anaesthetic gases and many other gases (due to van der Waal's attraction between molecules).

**CHARLES' LAW** V proportional to T (at constant P)

**GAY-LUSSAC'S LAW** P is proportional to T (constant V)

**DALTON'S LAW OF PARTIAL PRESSURES**  
 The pressure exerted by a mixture of gases is the sum of the individual pressures exerted by each gas.

**GRAHAM'S LAW** The rate of diffusion of gases through certain membranes is inversely proportional to their molecular weight. Useful to describe gas transport across the alveoli or the placenta. See also Fick's law.

**FICK'S LAW** The rate of diffusion of a gas across a barrier is proportional to the concentration gradient for the gas. Applicable to gas flows across lung and placental membranes. See also Graham's Law.

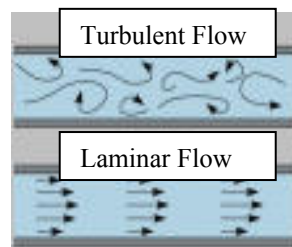
**HENRY'S LAW** The mass of a gas dissolved in a given amount of liquid is proportional to the pressure of the gas at constant temperature: gas concentration in solvent = constant x pressure (at constant T).

**CRITICAL TEMPERATURE** Temperature above which an increase in pressure cannot yield liquefaction. (N<sub>2</sub>:36.5 C; CO<sub>2</sub>:31.1 C; O<sub>2</sub>:-118 C)

**PRESSURE AND FLOW** Pressure is force per unit area and is measured in pascals (Newtons force per square metre), although mm Hg [Torr] is in common clinical use. Flow is pressure difference divided by resistance. If the flow is 100 mL/sec at a pressure difference of 100 mm Hg, the resistance is 100 mm Hg/100 mL/sec = 1 mm Hg/mL/sec.

**LAMINAR VS TURBULENT FLOW**

In laminar flow systems the resistance is constant, independent of flow, and Poiseuille's law is followed. Flow velocity is zero



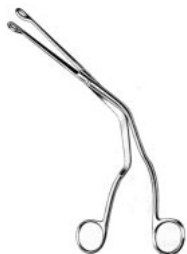at the edges of the tube, and maximum in the middle. When turbulence occurs, the flow pattern becomes unstructured, and the resistance increases with flow.

## SOME INTERESTING AIRWAY CASES

### Concealed Illegal Drugs Lead to Airway Obstruction

A 41 year old man was brought to a hospital Emergency Department (ED) after collapsing. He had been arrested ten minutes earlier on suspicion of illegal drug possession and was seen to swallowing his merchandise at the time of the arrest. While in the police vehicle the man became apneic, requiring a hospital diversion prior to incarceration. On arrival in the ED the man "was distressed, deeply cyanosed, and had marked upper airway obstruction". At laryngoscopy a foreign body was seen to be obstructing the glottic inlet and was removed using Magill forceps. (The foreign body turned out to be a folded bank note containing a small bag of white powder.) Removal of the obstruction resulted in immediate clinical improvement.

**Reference** Nathanson M, Watson D. Concealed illegal drugs: an actual cause of airway obstruction. *Anesth Analg* 1993; 865-866.



**Magill forceps: not just for nasal intubations.**

### Dental Appliance Gets in the Way

A 14 year old girl was scheduled as an outpatient for laser excision of vaginal condylomata. "She had full mouth braces, and attached to her lower teeth across the floor of the mouth was an orthodontic appliance" intended to discourage thumb sucking. This appliance was permanently adherent to the mandibular teeth and required removal by a dentist familiar with the design of the appliance. On bedside oropharyngeal examination, the soft palate could be seen, but not the posterior pharynx or tonsillar pillars (Mallampati Class III). The patient chose awake intubation over regional anesthesia for the procedure (both were offered) and fiberoptic intubation was attempted but was unsuccessful (reason not given), with the airway later secured blindly. After intubation and adequate anesthesia direct laryngoscopy was attempted to further assess the airway, but proved to be difficult, requiring that the laryngoscope be "positioned on the right side of the mouth."

**Discussion** Obviously, removal of the appliance is another possibly more prudent, option to consider. In the event that no dentist is available to remove the appliance, the patient could also be sent to her orthodontist for its removal. (However, this is not without trouble and expense to the patient, many of whom are not insured for dental care).

**Reference** Gurkowski MA, Knape KG, Bracken CA. Dental appliance can complicate an otherwise normal airway. *Anesth Analg* 1993; 77:865

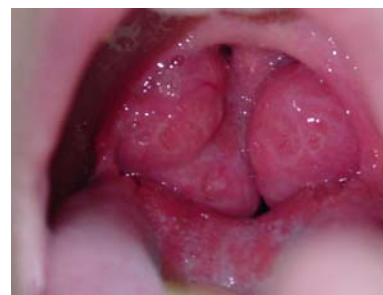### A Newspaper Clipping Tells it All

A newspaper clipping tells the tragic story (Montreal Gazette Feb. 1994): "The death of a woman during childbirth at LaSalle General Hospital could have been avoided if doctors had checked her respiratory tract before anesthetizing her for a caesarean birth, a coroner says." According to the coroner "the woman died of asphyxiation and heart failure during surgery because doctor hadn't checked to see whether she would be able to breathe while unconscious". According to the newspaper account, the patient had a rare condition where the back of her tongue covered "nearly all her throat" and noted that the patient "was unable to breathe through the face mask" applied to her face. After the doctors "tried several times to give her oxygen through tubes" (but failed because they were all too large), a surgical airway was attempted, but cardiac arrest occurred before the airway could be secured, and the patient died.

**Discussion** Hypertrophy of the lingual tonsils is an unusual condition that may cause complications such as airway obstruction, abscess, sleep apnea, and recurrent epiglottitis. While some lesions are visible at the bedside (e.g. while checking the Mallampati classification of the patient's oropharynx), many others may not be visible at all without special tools generally used only by ENT specialists. In this respect, the coroner may have been unfair in his judgment. A similar tragedy involving a 24-year-old woman whose markedly hypertrophied lingual tonsils prevented intubation after anesthetic relaxation during preparation for appendectomy has been reported by Cohle et al (1993). The huge hypertrophic tonsils totally obstructed the glottic aperture after induction, resulting in a "can't intubate/can't ventilate situation". A recent review of the literature has been published by Ovassapian et al. (2002).

**References** Cohle SD, Jones DH, Puri S. Lingual tonsillar hypertrophy causing failed intubation and cerebral anoxia. *Am J Forensic Med Pathol* 1993 14:158-61

Ovassapian A, Glassenberg R, Randel GI, Klock A, Mesnick PS, Klawns JM. The unexpected difficult airway and lingual tonsil hyperplasia: a case series and a review of the literature. *Anesthesiology*. 2002;97:124-32.



**ABOVE: Tonsillar hypertrophy can easily lead to airway obstruction. It can particularly difficult to detect in the case of lingual tonsillar hypertrophy.**

### Infected Laryngocele

A 42 year old man was seen for hoarseness and an enlarging left neck mass. Palpation revealed a 5 cm x 6 cm nonmobile swelling in the anterior triangle of the neck. As the mass increased in size, the larynx was pushed to the right side of the neck while dysphagia and worsening of the hoarseness occurred. Anesthesia to allow examination and biopsy was first attempted by maintaining spontaneous breathing under halothane, supplemented by methohexitone as needed, but this led to airway obstruction despite changes in posture and the use of oro- and nasopharyngeal airways. The patient was, therefore, allowed to awaken. A second intubation attempt was then launched using fiberoptic bronchoscopy via the right nares. The authors comment on what they saw: "This revealed a large polycystic lesion that arose from the left pyriform fossa with surrounding mucosal edema and inflammation. The epiglottis was lying distorted and compressed to the right and only the right arytenoid and vocal cord could be seen". Entry into the trachea was achieved by advancing the scope through an air bubble lying across the cords. Otherwise, the fiberoptic intubation proceeded uneventfully. At surgery a large laryngopyocele was excised through an external neck incision. Extubation (while fully awake and reversed) was uneventful.

**Discussion** While most laryngoceles are asymptomatic, compression of the tracheal lumen may lead to stridor, while injury to the vocal cord apparatus may lead to hoarseness (internal laryngoceles). With external laryngoceles, a neck swelling anterior to the sternomastoid muscle may sometimes be found. Should a laryngocele become infected it is renamed a laryngopyocele, often with symptoms of dysphagia, sore throat, cough or other complaints. Soft tissue neck x-rays (AP, lateral) may reveal laryngeal air sacs or an air-fluid interface (laryngopyocele).

**Reference** Rashid J, Warltier B. Awake fiberoptic intubation for a rare cause of upper airway obstruction - an infected laryngocele-an infected laryngocele. *Anaesthesia* 1989; 44:834-836.

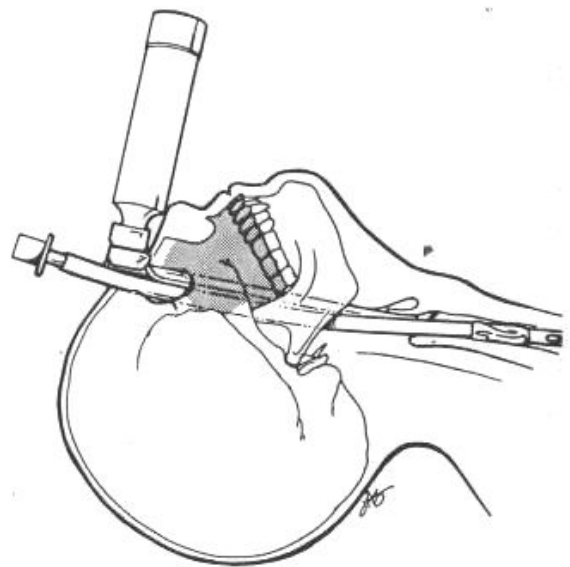
### Transorbital Intubation

A 35 year old man with recurrent maxillary adenocarcinoma was scheduled for excision of the right parotid gland. Half a year earlier he underwent an orbital exenteration with maxillary prosthesis placement and right maxillectomy under tracheostomy anesthesia. He was now unable to open his mouth over 1.5 cm, obviously not enough to admit a laryngoscopy. However, with this patient, removal of permanent maxillary prosthesis revealed an empty right orbital cavity "with the inferior skeletal surface absent, so that the base of the tongue could be visualized by looking from above the patient's head." Clinical examination revealed that he was breathing predominantly via the orbital cavity rather than through the nose (which was heavily scarred). Placement of the size 8 endotracheal tube was achieved by spraying the right orbit with topical anesthetic and using a laryngoscopy

equipped with a size 3 Miller blade. The epiglottis was visible from the vantage point, making intubation easy.

**Discussion** Fiberoptic intubation would likely also work in this setting, although in this case excessive secretions messed things up. One other thing should be noted: this patient would likely be impossible to ventilate by face mask, so if spontaneous ventilation is lost (e.g. from excessive sedative drug administration) it's all over unless an endotracheal tube is in place.

**Reference** Foreoughi V, Williams EL, Ferrari HA. Transorbital endotracheal intubation after maxillectomy and orbital exenteration. *Anesth Analg* 1994; 79:801-802



---

### Cardio-Pulmonary Bypass to Get the Airway

A 65 year old woman was diagnosed with asthma following symptoms of an upper respiratory infection and the development of wheezing. Treatment "with aminophylline, antibiotics, hydrocortisone and salbutamol (albuterol)" was unsuccessful, and she was transferred to a teaching hospital in respiratory distress. While a portable x-ray of the chest was unremarkable, "soft tissue films of the neck and tomograms of the trachea revealed an oval mass in the tracheal lumen just below the thoracic inlet at the level of the upper aspect of the aortic arch arising from the right lateral wall and almost completely occluding the tracheal lumen". Heliox (70/30 He/O<sub>2</sub>) was given by face mask, but without help. It was clear that urgent airway control was needed. It was also clear, given the tomographic findings, that intubating through the mass in the airway could be extremely hazardous (e.g. vascular tumor, aortic aneurysm compressing the trachea, etc.). The team chose to carryout femoral-femoral cardiopulmonary bypass under local anesthesia following 20,000 units of IV heparin. Halothane was administered through the pump, with IV fentanyl and pancuronium. Rigid

bronchoscopy with biopsies were taken, revealing a squamous cell carcinoma. The ETT was left in place postoperatively.

Later, investigations revealed metastases to two ribs, so tracheal resection surgery was not offered. Instead she received palliative radiotherapy to shrink the mass and given a permanent tracheostomy on day 10 of her hospital stay.

**Discussion** Tracheostomy under local anesthesia was not considered “because of the low-level of the mass”. Alternative approaches would include using fiberoptic bronchoscopy to check out the inside of the trachea, or perhaps using a rigid bronchoscope to secure the airway until a tracheostomy can be performed. This case illustrates the maxim “All that wheezes is not necessarily asthma”. Although the obstructing lesion was a squamous cell carcinoma, a similar clinical picture may occur with severe tracheal stenosis or foreign body impaction in the airway.

**Reference** Jensen V, Milne B, Salerno T. Femoral-femoral cardiopulmonary bypass prior to induction of anaesthesia in the management of upper airway obstruction. *Can Anaesth Soc J* 30:270-272, 1983.

### Asymptomatic Epiglottic Cysts as a Cause of Upper Airway Obstruction During Anesthesia

Mason and Wark present two cases of asymptomatic epiglottic cysts which presented as partial upper airway obstruction following induction of anesthesia .

**CASE 1.** A 55-year-old male admitted for elective repair of a left inguinal hernia and banding of haemorrhoids was noted to have difficult ventilation of the lungs by hand. Laryngoscopy revealed a large 4-5 cm cyst arising from the vallecula. The cyst completely obstructed the view of the epiglottis and vocal cords. Blind intubation was unsuccessful. An ENT senior registrar performed direct laryngoscopy and 20 ml of clear serous fluid was aspirated from the cyst using a 21-gauge needle and syringe. Tracheal intubation was then performed easily.

**CASE2.** A 51-year-old woman, presented to dental outpatients for dental clearance, had previously received uneventful general anesthetics in the past. She smoked 15 cigarettes a day, complained of a mild, dry, morning cough and her husband complained that she snored at night. A large cyst (3-4 cm in diameter) was seen in the vallecula. As a result neither the epiglottis nor the vocal cords could be seen. Several attempts at intubation were unsuccessful and due to profuse bleeding from the nasopharynx, the procedure was abandoned. Two weeks later the cyst was incised thus expressing 30 ml of a thick, cream-like material. The dental clearance proceeded uneventfully. A follow-up laryngoscopy showed no recurrence of the cyst.

**Reference** Mason DG, Wark KJ. Unexpected difficult intubation. Asymptomatic epiglottic cysts as a cause of upper airway obstruction during anaesthesia. *Anaesthesia* 1987; 42:407-10

---

### Pharyngeal Pouch as a Cause of Difficult Intubation

In a case reported by Bray, the presence of a lateral pharyngeal pouch caused difficulty in recognizing the glottis when awake intubation was attempted on a newborn. This was due to the fact that the orifice opened and closed during phonation and was therefore mistaken for the glottis.

**Reference** Bray RJ. Pharyngeal pouch as a cause of difficult intubation. *Anaesthesia*. 1977; 32:333-5.

---

### Intubating with the Patient in the Prone Position

It has been suggested that epiglottic cysts might be handled by tracheal intubation with the patient in the prone position. How to do it? “The patient is turned and lifted up the table with the head supported by one assistant so that the chin is clear of the top end of the table.” Intubation is then done in the kneeling position with the laryngoscope in the right hand and the tube held in the left. Got that? (Note: “The technique is easy, but rehearsal is essential”)

**Reference** Middleton H. Tracheal intubation with the patient prone. *Anaesthesia* 1989; 44:940

---

### Perforated Esophagus

A 67 year old man developed a severe asthmatic attack leading to respiratory arrest. Intubation was difficult, but was achieved after several attempts. Soon after, subcutaneous emphysema appeared in the neck and chest and spread to the face and abdominal wall. The presumptive diagnosis of a perforated esophagus was confirmed by a gastrografin swallow study showing an esophageal leak into the mediastinum. Broad spectrum antibiotics were started.

**Discussion** Fortunately, surgical repair of the esophagus was not needed in this case. Still, this case reminds us of the many potential complications associated with intubation.

**Reference** Eldor J, Ofek B, Abramowitz HB. Perforation of oesophagus by tracheal tube during resuscitation. *Anaesthesia* 1990; 45:64-64.

---



### A Case of Complete Tracheal Transection

A drunk 28 year old man sustained C2-C3 and chest injuries in a motor vehicle accident. He was intubated nasally in the Emergency Room and brought to the OR “awake, combative, and neurologically intact” for a right thoracotomy. Fiberoptic bronchoscopy before the anesthetic revealed a 5 cm gap between the ends of a completely transected trachea. During

the surgery the lungs became harder to ventilate, with high airway pressures and later hypotension and bradycardia ensuring. Mediastinal emphysema and poor lung expansion were noted by the surgeons. The anesthesiologist recognized that unless an ETT could be made to reach beyond the (now 8 cm) tracheal gap, the airway would be irrevocably lost.

However, the ordinary 33-cm ETTs were too short, so a long ETT was fashioned from two regular tubes by making one into an extension piece, with both pieces bridged by a 15-mm connector segment fashioned from the ETT connector. Postoperatively the special nasal ETT was sutured in place for 18 days to serve as a tracheal stent. Extubation was uneventful.

**Reference** Holzman RS. A tracheal tube extension for emergency reanastomosis. *Anesthesiology* 1989; 70:170-171

---

### A Case of Pediatric Macroglossia

A 20 month old girl underwent a cleft palate repair using a size 4.0 ETT. At the end of the procedure the child was extubated awake, but the child immediately developed dyspnea. Bag/mask ventilation was difficult, as if an obstruction to ventilation were present. Reintubation was eventually achieved after five attempts. Subsequent endoscopy in the ICU “revealed a swollen tongue and supraglottic region” while ultrasonography of the tongue “showed homogeneous tissue without evidence of abscess or other cystic abnormality.” The edema delayed extubation until postoperative day 18.

**Discussion** The authors suggest this complication occurs more frequently with cleft-palate repairs exceeding 3.5 hours as “a longer procedure implies longer retractor times”, as well other potential problems. In the second case of their report reintubation was similarly very difficult, in fact unsuccessful, and the child sustained a cardiac arrest resulting in severe neurological damage.

**Reference** Patane PS, White SE. Macroglossia causing airway obstruction following cleft palate repair. *Anesthesiology* 1989; 71:994-995.

---

### Crico-tracheal disruption and carotid artery occlusion

A 20-year-old male suffered a clothesline injury to his anterior neck while driving an all terrain vehicle (ATV). Symptoms included hoarseness, dysphagia, dyspnoea and neck swelling, all being referable to the upper respiratory tract.

Subcutaneous emphysema was revealed by lateral x-rays of the neck and he was immediately transferred to the operating room for tracheostomy under local anesthesia. The patient was transferred from the peripheral hospital to a larger institution. The anterior neck was severely contused, however, the patient was moving all extremities. The crico-tracheal separation was repaired in the OR. A tracheostomy was created. 48 hours after the initial injury there was no spontaneous movement of his left arm or leg. A CT scan

revealed a large radiolucent area involving the right frontal and parietal lobes consistent with a large cerebral infarct. Occlusion of the right common carotid artery was demonstrated by angiography. 120 hours after the initial injury the patient died following the development of intractable cerebral edema.

**Reference** Oxorn D, Clark K. Crico-tracheal disruption and common carotid artery occlusion: a case of blunt trauma. *Can J Anaesth* 1990;37:913-5

---

### Fetal Tracheal Intubation with Intact Uteroplacental Circulation

Schulman et al. reported on two cases of fetal tracheal intubation with intact uteroplacental circulation.

**Case I:** A 35-year-old woman at 36 weeks gestation had a prenatal ultrasound revealing an 8 x 10 cm neck mass in the fetus. A c-section was performed and the fetal head was delivered to the shoulders. An 8 x 10 cm hemangioma involving the left side of the face and neck was revealed upon examination. Direct laryngoscopy was performed while maintaining an intact uteroplacental circulation. Rightward lateral displacement of the larynx and trachea was caused by the hemangioma. The trachea was intubated nasally with some difficulty. Delivery was completed once the airway was secured. (During intubation the placenta was used as the organ of gas exchange). Computed tomography of the head and neck revealed that the hemangioma was fed primarily by branches of the left external carotid artery. Signs of congestive heart failure developed and were treated and a diagnosis of Kasavack-Merritt syndrome was made. Partial excision of the cervical portion of the hemangioma was carried out in the operating room. Steroids further shrunk the remaining portion of the hemangioma. She did well.

**Case II** An 1840 g 30 wk preterm infant was delivered by cesarean section. Prenatal ultrasound revealed a large pharyngeal mass in the fetus. Following delivery of the fetal head and shoulders, a 10 x 10 cm teratoma protruding from the oropharynx was noted. Difficult intubation was carried out while the fetus continued to receive oxygenated blood from the placenta. Once the airway was secured, the remainder of the baby was delivered. Signs of poor perfusion were shown, however, subsequent improvement in perfusion occurred after venous access was obtained and also upon receiving two boluses (10 mL/kg) of 5% albumin. Following the initial period of stabilization (1 hr), the teratoma was surgically excised in the operating room. Although successful, the infant succumbed at 12 days due to complications associated with prematurity.

**Reference** Schulman SR, Jones BR, Slotnick N, Schwartz MZ Fetal tracheal intubation with intact uteroplacental circulation. *Anesth Analg* 1993;76:197-9

---

### Cervical Goiter

A 60 year old woman presented to hospital with wheezing, dyspnea and intolerance of lying supine. Two months earlier, she had noticed progressive hoarseness and a sense of "fullness" in her chest. The CXR obtained on admission "showed a left upper mediastinal mass with displacement of

the cervical and thoracic trachea to the right". A thyroid scan revealed a cold nodule with "an area of nonhomogeneous uptake extending into the mediastinum", while CT showed "posterior displacement of the trachea and compression of the aorta and brachiocephalic vessels." The dyspnea was too severe to permit flow-volume loop testing. Intubation with a double lumen ETT (39-Fr, L-sided) was chosen for the resection surgery. Earlier bronchoscopy showed "that the entire anterior surface of the thoracic trachea buckled inward during expiration and that the right mainstem bronchus was almost completely occluded at the carina throughout the respiratory cycle." After the DLT was "passed orally under direct vision between the vocal cords" with the patient awake and breathing spontaneously" exact positioning was achieved using a 4.2 mm OD bronchoscope. General anesthesia was achieved by "inhalation of increasing concentrations of halothane in oxygen" and by maintaining spontaneous breathing until the chest was opened; controlled ventilation was used thereafter until she died from an unexpected myocardial infarction.

**Discussion** In the course of caring for the patient, fiberoptic inspection of the airway provided useful information. Consider this description obtained on the first postoperative day: "The proximal 7 cm of the cervical trachea buckled with spontaneous respiration, although the distal thoracic trachea now appeared structurally normal" The choice of a left-sided DLT allowed one to keep open the partially occluded left

mainstem bronchus, while "spontaneous ventilation was employed to avoid the possibility of air trapping distal to the obstruction in the right mainstem". The authors conclude their report by noting how much more useful is fiberoptic bronchoscopy as compared to, say, flow volume loops or preoperative radiation therapy. They note that fiberoptic tracheo-bronchoscopy "is essential for direct preanesthetic evaluation of dynamic airway anatomy and for accurate endotracheal tube placement"

**Reference** Younker D, Clark R, Coveler L. Fiberoptic endobronchial intubation for resection of an anterior mediastinal mass. *Anesthesiology* 1989; 70:144-146

---

### Parturient with Tracheal Stenosis

A 31 year old woman at 37 weeks gestation was referred for tracheal dilatation because of dyspnea and biphasic stridor at rest. Bronchoscopy "revealed severe subglottic stenosis with a 3-mm tracheal lumen." As the added work of breathing presented by the stenosis was not compatible with the ventilatory requirements for labor, it was decided to carry out a balloon dilatation of the trachea. This was done under local anesthesia as follows: "A flexible fiberoptic bronchoscope was passed through the larynx so that a clear view of the proximal end of the stenosis was seen. The stenosis originated 2 cm from the glottis, was 3-4 mm in diameter, and appeared web-like... A balloon-tipped catheter was advanced via the trachea within the stenosis. At this time, the patient was asked to hold her breath and the balloon was inflated to 60 PSI for 20 seconds to dilate the stenotic area. After a brief respite for the patient, the procedure was repeated." At immediate followup bronchoscopy the web-like stenosis had been cleared, while the patient had immediate subjective improvement. Mother and baby did fine thereafter.

**Discussion** Other options exist in managing tracheal stenosis, including laser surgery to excise stenotic tissue, tracheal resection surgery or tracheal stenting. The method of balloon dilatation can be done under local anesthesia and is relatively less invasive, likely advantages in a pregnant patient.

**Reference** Salama DJ and Body SL. Management of a term parturient with tracheal stenosis. *British Journal of Anaesthesia* 1994; 72:354-357.

---

### Epidermolysis Bullosa (EB)

A 20 year old woman with EB was to have surgery to treat vaginal agglutination. She had bullae and scars all over and had limited mouth opening because of lateral scarring. Regional anesthesia to T12 was achieved using a 25-gauge spinal needle at L2-3 with 10 mg of hyperbaric tetracaine.

**Discussion** Epidermolysis bullosa (EB) is a terrible cutaneous disease with disrupted cohesion between the dermis and epidermis layers of the skin. Even trivial skin trauma results in the formation of vesicles, bullae and ulcers, often with

subsequent scarring. Esophageal strictures may necessitate dilatation under anesthesia, while malnutrition, anemia and cutaneous infections are ever present concerns. Tape applied to the patient will end up ripping off skin. Intravenous access is often difficult. No wonder most anesthesiologists don't want to mess with the airway and thus opt for a regional anesthetic technique. Clinicians familiar with EB note that laryngoscopy and intubation, or even insertion of an oral airway or an LMA may result in damage to the oral mucosa. Another option to consider in these patients is ketamine, as it provides both good analgesia and tends to maintain airway-related reflexes. However, ketamine has several annoying flaws: airway protection is imperfect (aspiration can occur), no muscle relaxation is provided, and it has a hyperdynamic effect on the intact heart (obviously desirable in hypovolemic patients, but not at issue here). Recovery may include unpleasant dreams and senseless babbling by the patient; clinical folklore suggests that this problem can be reduced by also using a benzodiazepine.

**Reference** Sperlman FJ, Mann ES. Subarachnoid and epidural anesthesia for patients with epidermolysis bullosa. *Can Anaesth Soc J* 1984; 31:549-551.

---

### Respiratory Obstruction in a Behcet's Syndrome Patient

A 37 year old woman was admitted for treatment of multiple mucosal lesions in the oropharynx. Four years later, she was admitted for repair of a rectovaginal fistula. On preoperative examination a sore on the left buccal mucosa was noted. At

laryngoscopy, it was noted that "base of the tongue was fused to the soft palate, isolating the mouth from the pharynx by a sheet of scar tissue" with two small holes allowing ventilation. Intubation proved impossible (the holes being too small to admit an endotracheal tube), but ventilation by mask "could be maintained by slow pressure with bag and mask". Complete respiratory obstruction occurred when spontaneous ventilation was attempted. The anesthesiologist chose to start a 0.1% succinylcholine drip and administer N<sub>2</sub>O/O<sub>2</sub>/halothane by face-mask using positive pressure ventilation. A tracheotomy set and ENT surgeon were sent for in case a surgical airway became necessary. Surgery and recovery from anesthesia were uneventful. It later became apparent that the mucosal lesions she had four years earlier had been previously diagnosed as Behcet's Syndrome, a clinical syndrome consisting of "recurrent chancroid-type ulcerations of the mouth and genitalia, and repeated attacks of uveitis".

**Discussion** Continuing with a mask anesthetic using hand ventilation during elective major gynecologic surgery would today be regarded as overly adventurous given that it would likely be safest to wake up the patient and intubate the patient awake. This, however, would likely require some oral surgery under local anesthesia, for example, enlarging one of the two channels to admit an endotracheal tube. This creates a second set of issues (e.g. local anesthetic toxicity).

**Reference** Screech G. An unusual cause of respiratory obstruction during anaesthesia. *Brit J Anaesth* 1965; 37:978-9.

---

### Tracheal Stents: the Montgomery T-tube

A 29-year-old woman was admitted for reconstruction of subglottic tracheal stenosis. She currently had a tracheotomy tube in situ. No other major system abnormalities were revealed upon examination. Once the Montgomery T-tube stent was in place, laryngoscopy was easy, however, the ETT could not be passed without disturbing / dislodging the T-tube stent. Instead, a laryngeal mask airway (LMA) was placed and at no time was it necessary to remove the stent. The remainder of the procedure and recovery were uneventful.

**Reference** Mather CM, Sinclair R, Gurr P. Tracheal stents: the Montgomery T-tube. *Anesth Analg* 1993; 77:1282-4

---

### Thrombocytopenia Complicating Iatrogenic Cushing's Syndrome

A 30 year old woman with Idiopathic Thrombocytopenic Purpura (ITP), also more correctly known as Autoimmune Thrombocytopenic (ATP) [pathology: platelets are destroyed by antiplatelet antibodies] was to undergo emergent cesarean section at 33 weeks gestation. Platelets were always under 100,000 per cubic mm despite starting prednisone treatment (80 mg/day). Within a week of being put on steroids facial, neck and tongue swelling put the airway at risk, as evidenced by nocturnal dyspnea and a choking sensation while lying flat. This had worsened over time (the facial edema was now "massive"), while the platelet count was now at 63,000 per cubic mm immediately preoperatively. As if that was not enough, the patient was developing early pregnancy induced hypertension (PIH), and was obese. The patient received a blind nasal intubation via the left nostril using 5% ephedrine to vasoconstrict the nasal mucosa and 5% lidocaine ointment for lubrication. The left nostril was then dilated using size 30, then size 36 Fr latex nasopharyngeal airways, followed by a size 6.0 nasotracheal tube, which was successfully placed in under one minute. The surgery and extubation were uneventful, with minimal bleeding, possibly because of 8 units of platelets given before inducing anesthesia (Note, however, that hematologists often discourage this practice in ITP since the platelets given are quickly destroyed).

**Discussion** The authors considered, but dismissed, regional anesthesia because of an increased bleeding time (11 min. vs. maximum normal of 9 min.; IVY method) and because of the urgent nature of the surgery. Fiberoptic intubation was not chosen because they did not have a bronchoscope thin enough for a 6.0 ETT, a size felt to be especially appropriate in view of the considerable edema.

**Reference** Rosenberg DB, Gross JB. Awake, blind nasotracheal intubation for cesarean section in a patient with autoimmune thrombocytopenic purpura and iatrogenic Cushing's Syndrome. *Anesth Analg* 1993; 77:853-855.

---

### Impacted Epiglottis

A 54 year old otherwise healthy man was admitted for removal of a kidney stone. Anesthetic induction was uneventful and intubation was straightforward. Although "during the laryngoscopy prior to intubation, the epiglottis was seen to be occluding the glottic aperture", airway management with an ETT in-situ was always easy. About one-half an hour after release from the recovery room, while fully conscious and responding to commands, an "asphyxial episode" took place, with violent signs of complete upper airway obstruction and the patient attempting to scream "I'm choking". The crisis was resolved by reintubation. A second crisis occurred five to ten minutes after the second extubation, necessitating a third intubation. Four hours later, extubation was finally carried out without incident.

**Discussion** During the initial laryngoscopy, the epiglottis was seen to be obstructing the glottic aperture due to being "folded back on itself and acting as a jammed valve". Apparently, during severe laryngospasm (such as occurs frequently in children following guillotine tonsillectomy) the enormous negative airway pressures generated may actually force the epiglottis to fold over on itself. An addition concern in this setting (high negative airway pressures) is pulmonary edema.

**Reference** Morrow WFK. Respiratory obstruction due to impaction of epiglottis. *Brit J Anaesth* (1965), 37:980-981.

---

### Airway Rescue using a Laryngeal Tube (LT) in a Morbidly Obese Man

"A 50-yr-old morbidly obese man (weight, 275 kg; height, 172 cm; BMI = 93) was scheduled for bariatric surgery (open Rouxen Y gastric bypass). The patient had multiple medical problems: hypertension, insulin-dependent diabetes mellitus, venous insufficiency, and sleep apnea. He presented with normal airway anatomy, i.e., good mouth opening, three finger breadth thyromental distance, Mallampati class I but limited neck extension. Most of the weight was distributed on the lower trunk and body. The patient was optimally positioned on the OR bed for direct laryngoscopy (blankets under scapula, shoulders and neck raising the head and neck above the thorax) and noninvasive monitors were applied. After five minutes of preoxygenation rapid sequence induction (propofol, succinylcholine) was performed with cricoid pressure. Laryngoscopy revealed a grade 4 Cormack and Lehane view with no improvement after change of blades (Macintosh 3, 4 and Miller 3), release of cricoid pressure and thyroid manipulation."

"The difficult airway cart and help were summoned to the OR. Initially a two-hand face mask ventilation with an oral airway was acceptable but quickly deteriorated after the third laryngoscopic attempt. In this "cannot ventilate-cannot intubate" (CV-CI) situation with the oxygen saturation in the high 70s a #4 LT was inserted and inflated to 60 cm H<sub>2</sub>O. Good ventilation was possible (positive capnographic tracing, leak pressure of 35 cm H<sub>2</sub>O, no gastric insufflation and tidal volumes 600 to 650 mL. The fiberoptic view was poor, with no visualization of the glottic opening. No LT manipulation was attempted to improve the view. Chin lift and semi-sitting position increased the tidal volume (~ 750 mL). Vital signs were stable and the oxygen saturation increased to 95% in five minutes. CPAP (5-10 cm H<sub>2</sub>O) was maintained to assist spontaneous ventilation. After the patient responded to commands the LT was deflated and removed and he recovered in the OR in the sitting position using his own bilevel positive airway pressure device. Surgery was rescheduled and the patient was intubated with an awake nasal fiberoptic technique in the sitting position".

**Discussion** The morbidly obese can sometimes be particularly challenging to intubate. As this case illustrates, extra help is always valuable, and awake intubation is often the most prudent approach. Note also that many clinicians would question the wisdom of performing a rapid-sequence induction in such a patient, given that this technique is generally discouraged in any patient suspected to be difficult to intubate.

**Reference** Adrian A. Matic and John Olson. Use of the Laryngeal Tube in two unexpected difficult airway situations: lingual tonsillar hyperplasia and morbid obesity. *Can J Anesth* 2004 51: 1018-1021. [The reader is encouraged to read the full article, available free online at the CJA web site at <http://www.cja-jca.org/cgi/content/full/51/10/1018> This interesting article also includes a description of a case of a patient with lingual tonsillar hyperplasia who was also rescued using a laryngeal tube.]

---

Readers interested in more information on the laryngeal tube, illustrated below in a variety of sizes, may wish to read the following review article: T. Asai and K. Shingu. The laryngeal tube. *Br. J. Anaesth.*, 2005; 95: 729 - 736.

